4T Brain MRI Results

Antao Du, MD
Andreas Ebel, PhD
Geonho-Ho Jahng, PhD
Lana Kaiser, PhD
Susanne Mueller, MD
Lara Stables, PhD
Norbert Schuff, PhD
Xioaping Zhu, PhD, MD
Michael. M. Weiner. MD

VA Medical Center & University of California, San Francisco

Volumetric High-Resolution MRI

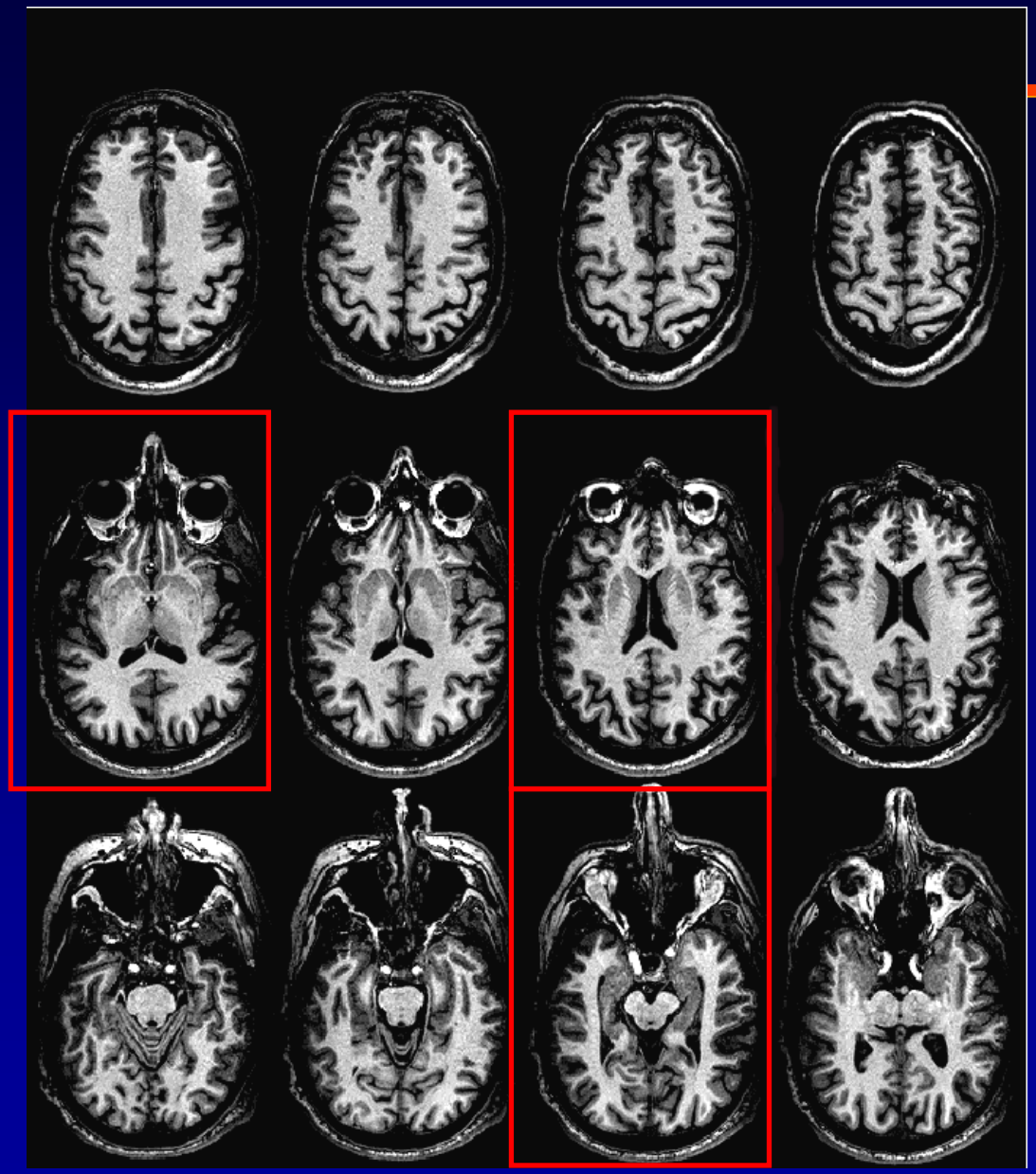

Volumetric High-Resolution FLAIR

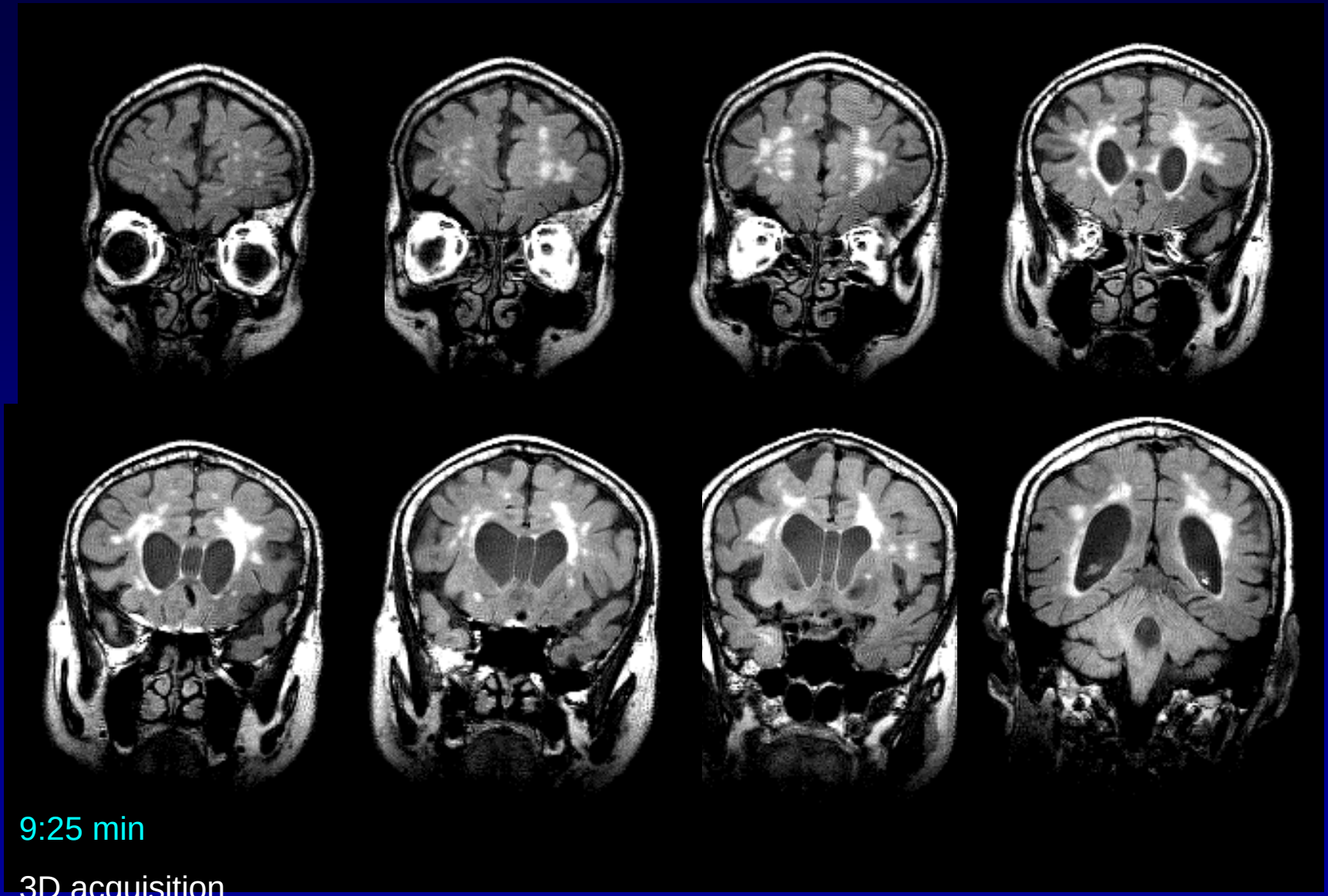

9:25 min

3D acquisition

Resolution: 1 x 1 x 1mm^3

Hippocampal Subfields

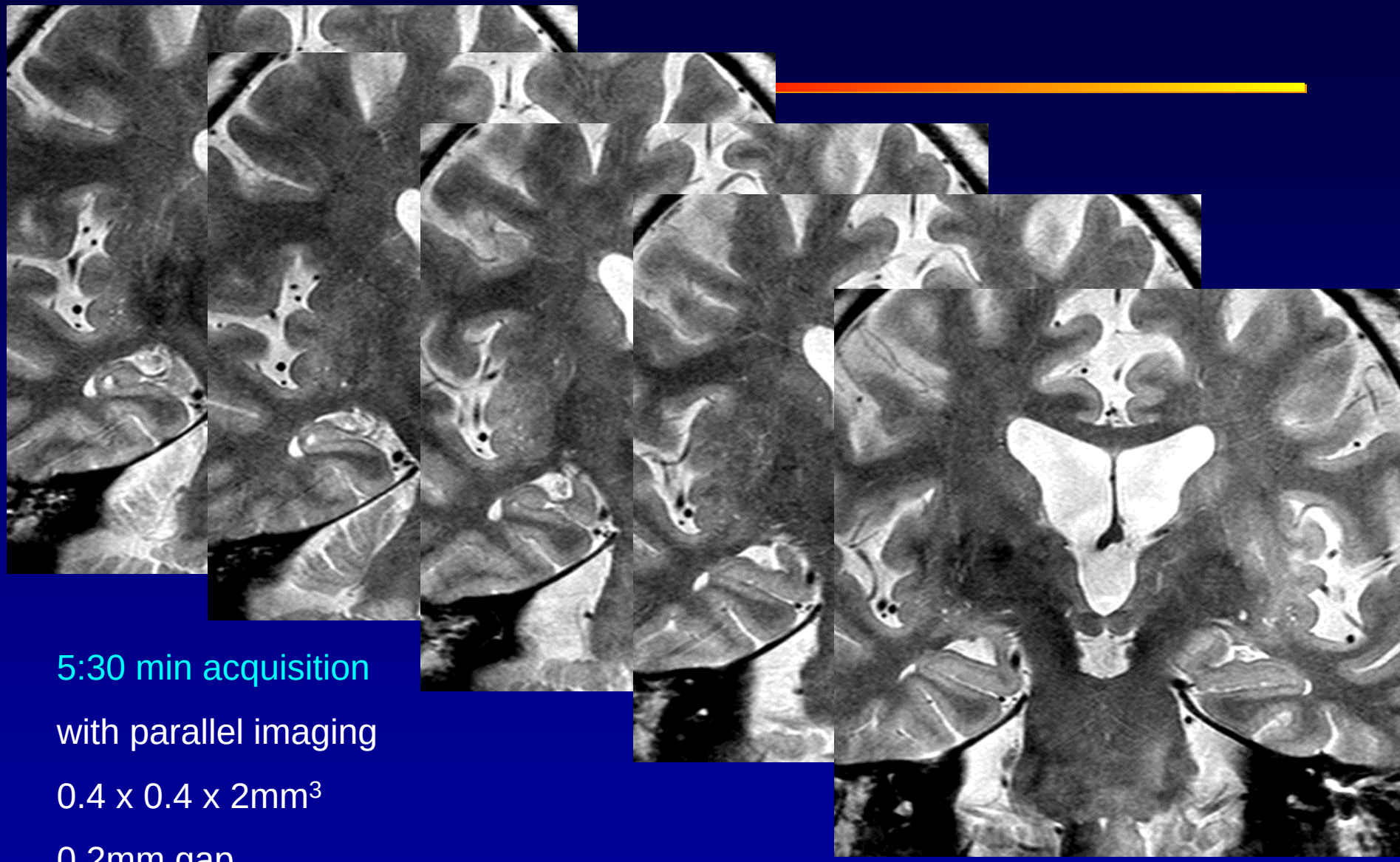

5:30 min acquisition

with parallel imaging

0.4 x 0.4 x 2mm^3

0.2mm gap

TSE

Hippocampal Subfields

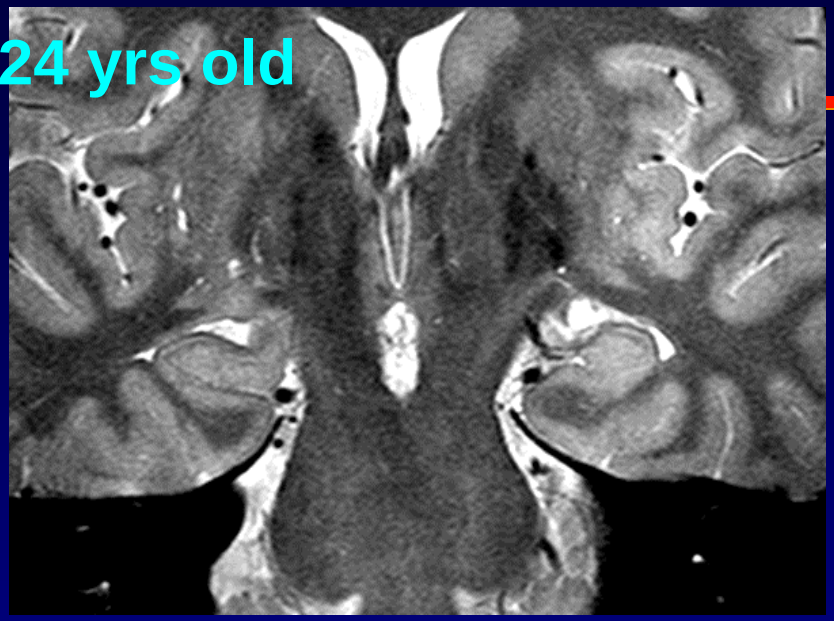

Protocol

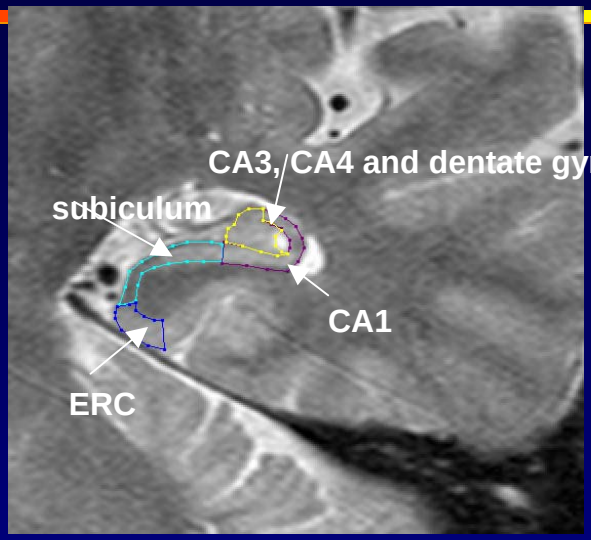

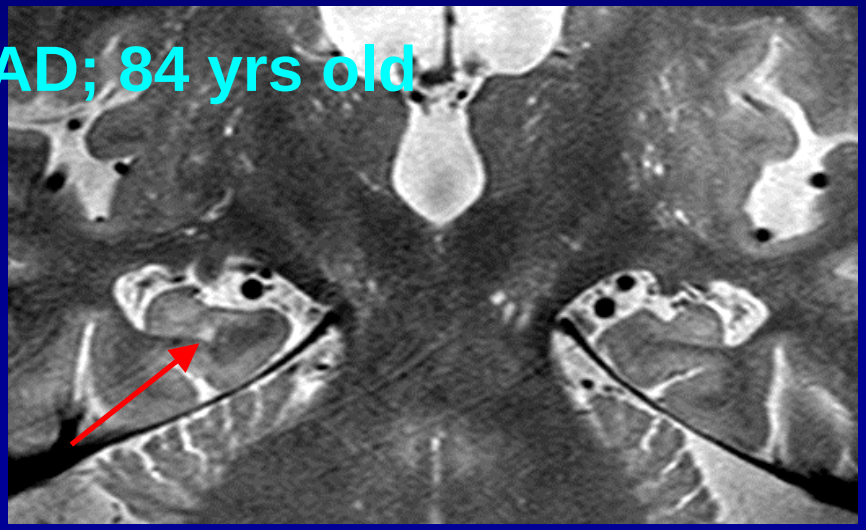

Rater Reliability

Region	Overall*	Rater A*	Rater B*
Left.ERC	0.71	0.83	0.67
Right.ERC	0.99	NA**	0.99
Left. Subiculum	0.79	0.99	0.91
Right. Subiculum	0.51	0.99	0.30
Left.CA1	0.93	0.99	0.98
Right.CA1	0.99	0.99	0.99
Left.CA2	0.83	0.79	0.91
Right. CA2	0.74	0.63	0.91
Left.Total	0.82	0.98	0.89
Right.Total	0.99	0.98	0.98

Age Effect on Subfields

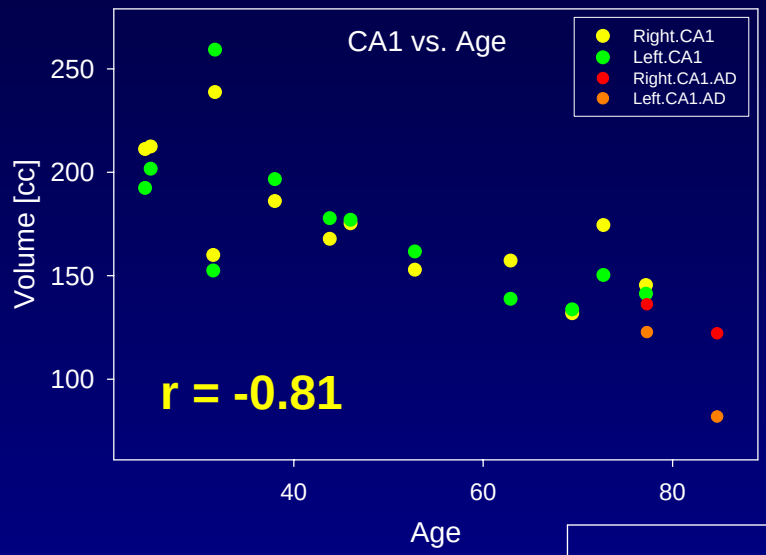

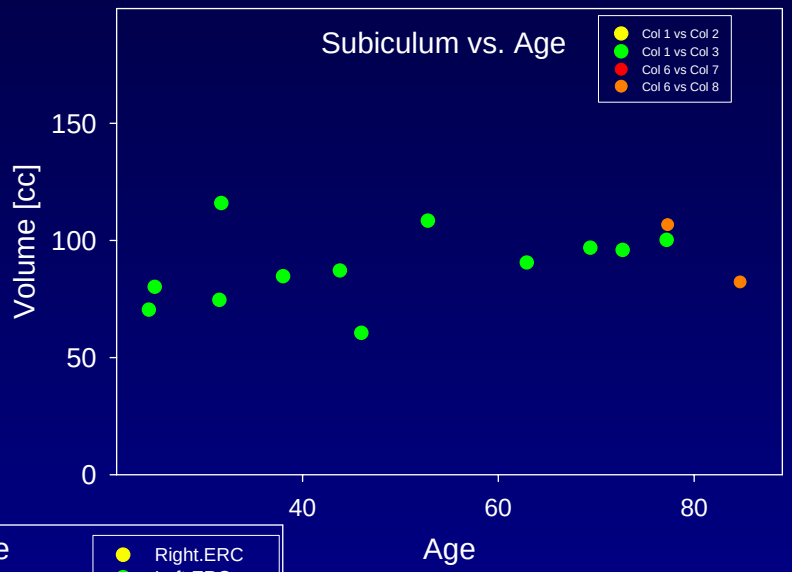

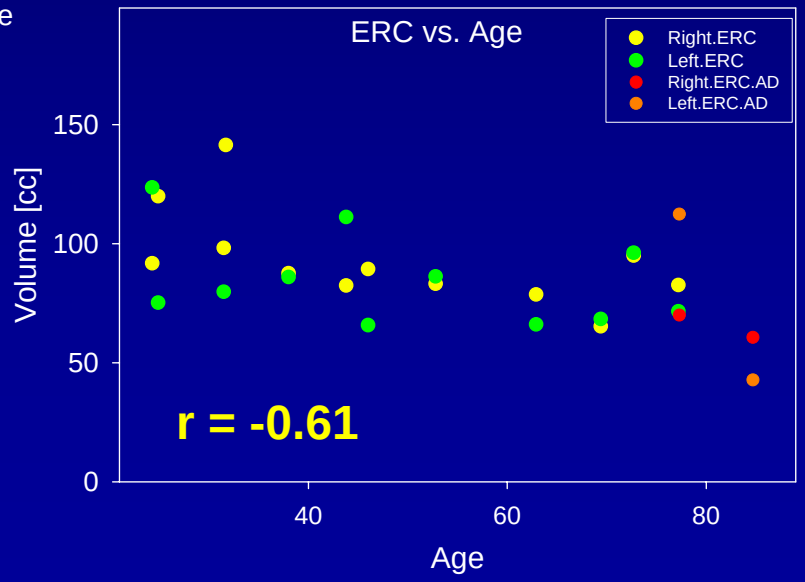

Continuous Labeling – Multislice Perfusion MRI

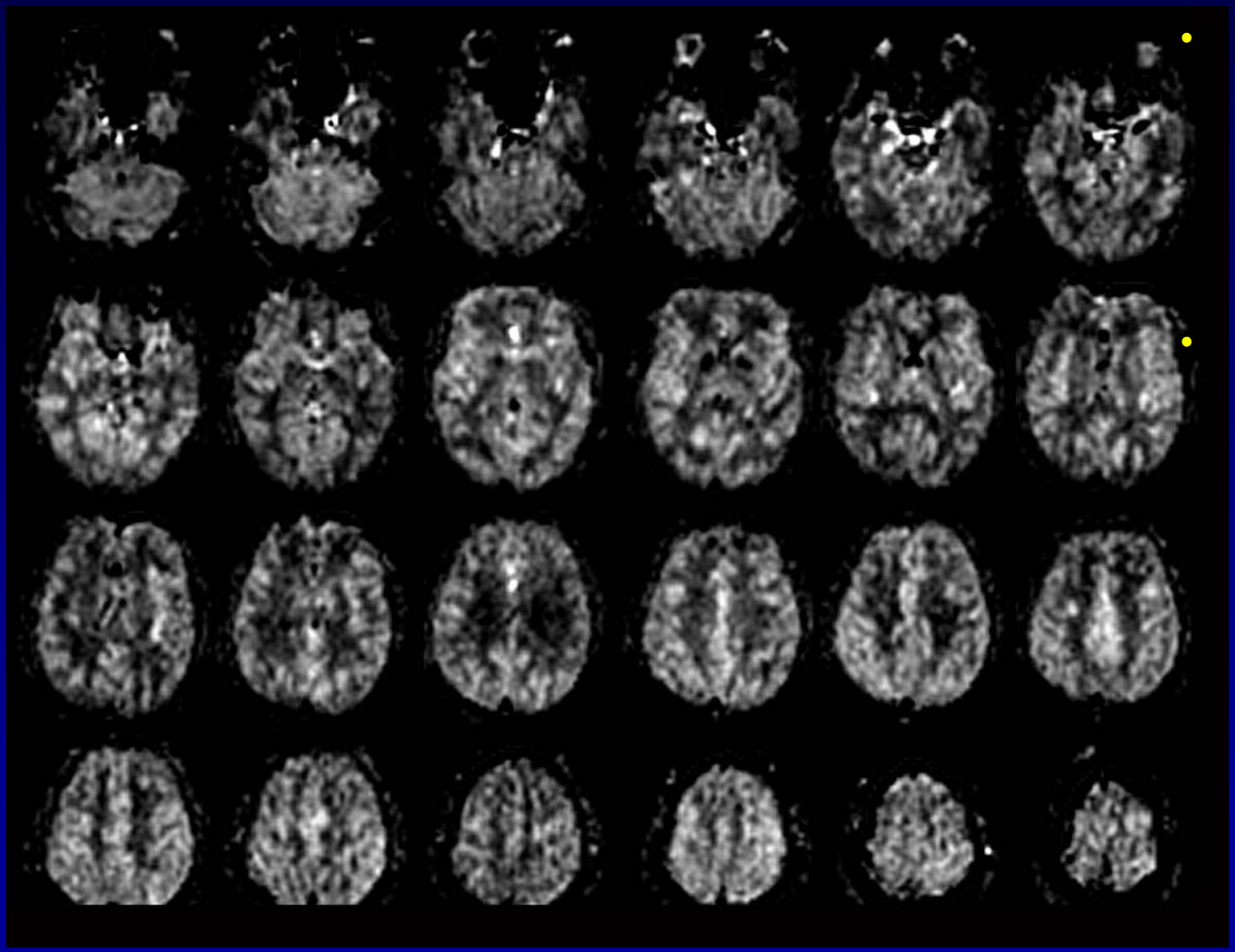

Authors

- Jiongjiong Wang
  John Detre
- Geon-Ho Jahng
  Norbert Schuff

Imaging Parameters:

- 8min
- 2.4mm x 2.4mm
- 3mm slices,
- 0.75mm gap;
- TR/TE=4200/11ms
- 120 averages

Pulsed Labeling – Volumetric Perfusion MRI

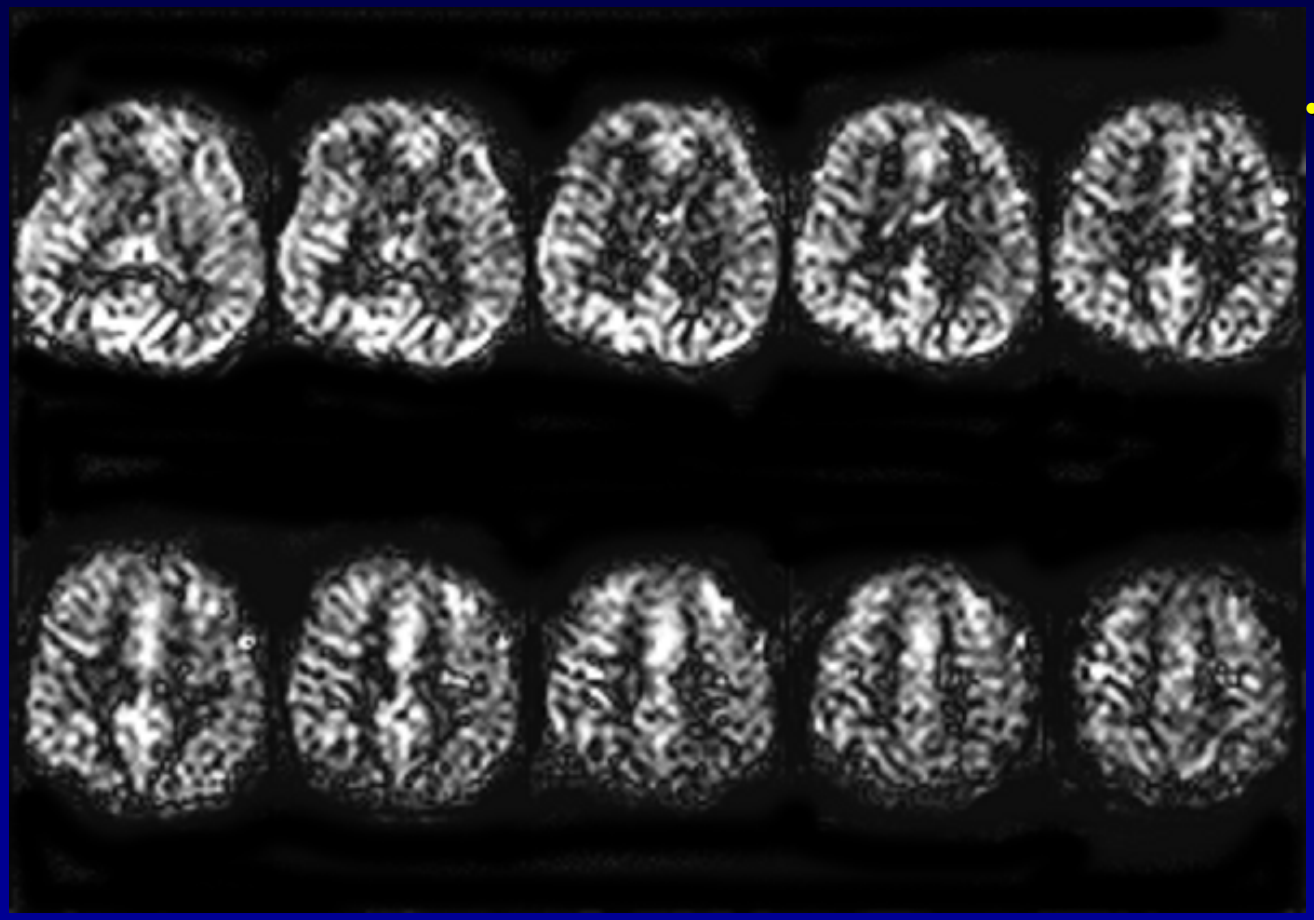

- **Imaging Parameters:**
  - **6min**
  - **4 x 4 x 4 mm**
  - **TR/TE=4200/11ms**
  - **50 averages**

Pulse Sequence courtesy of Drs. Feinberg and Guenther, MRI Advanced Technologies, Inc.

Preliminary ASL Results (4T)
Age-related Hypoperfusion

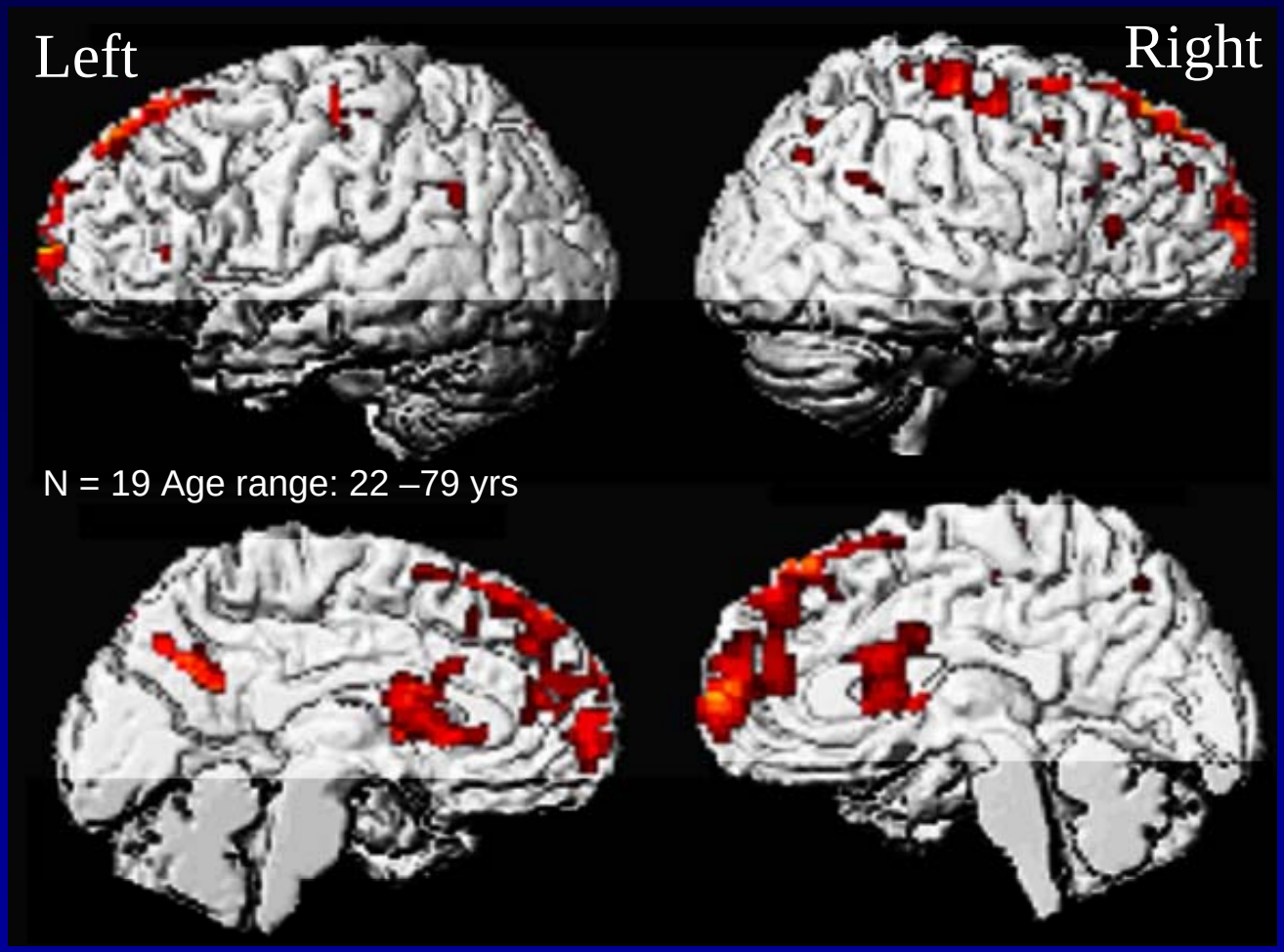

Regions with a significant correlation between reduced perfusion and increasing age.

Reduced Geometrical Image Distortions with Parallel Imaging

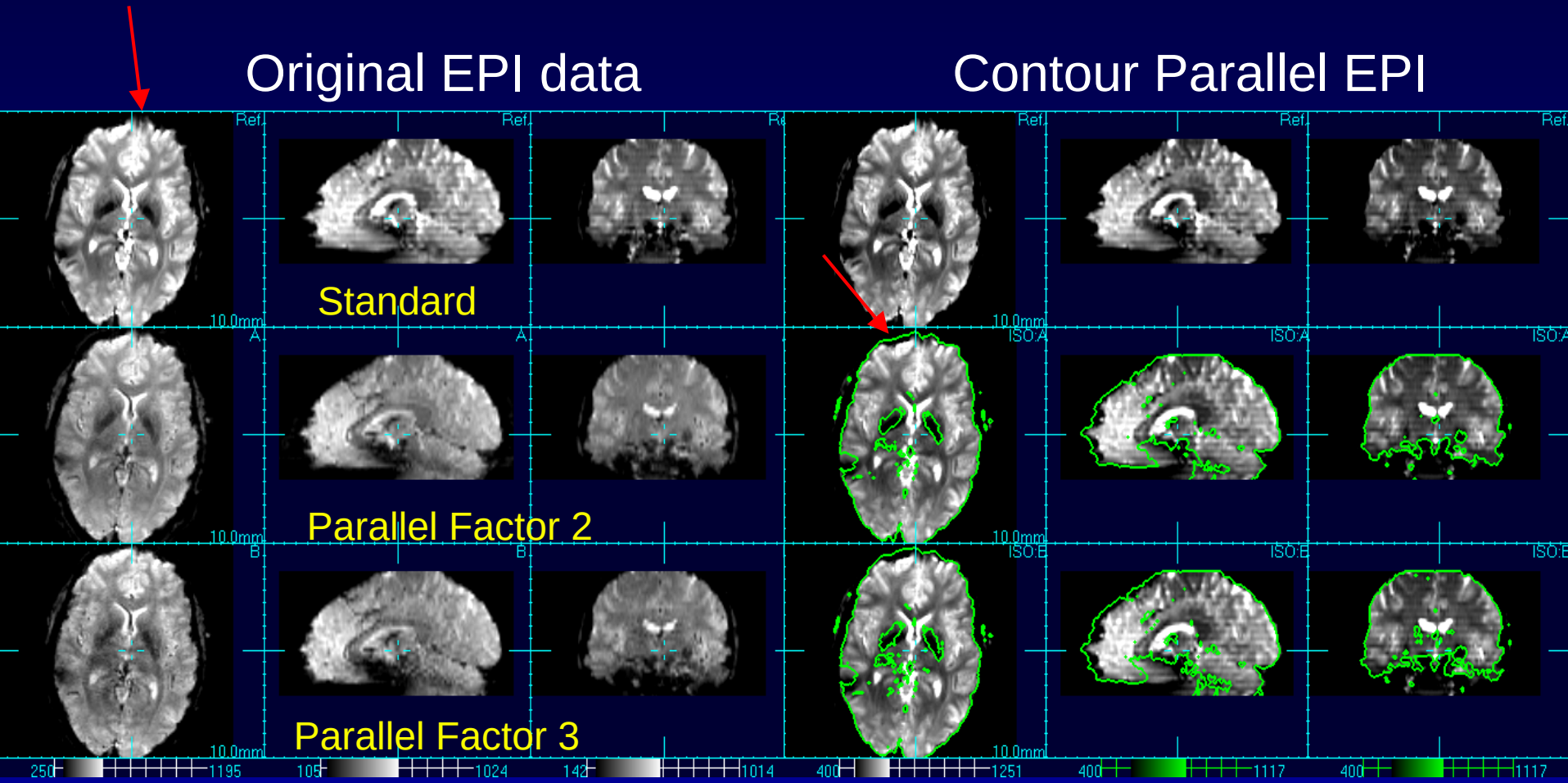

Single Voxel ^{1}H MR Spectroscopy

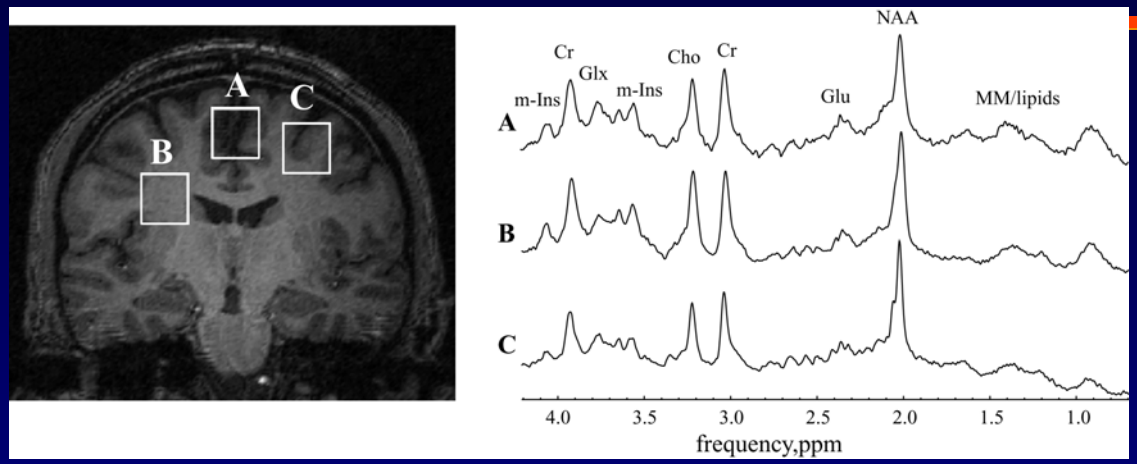

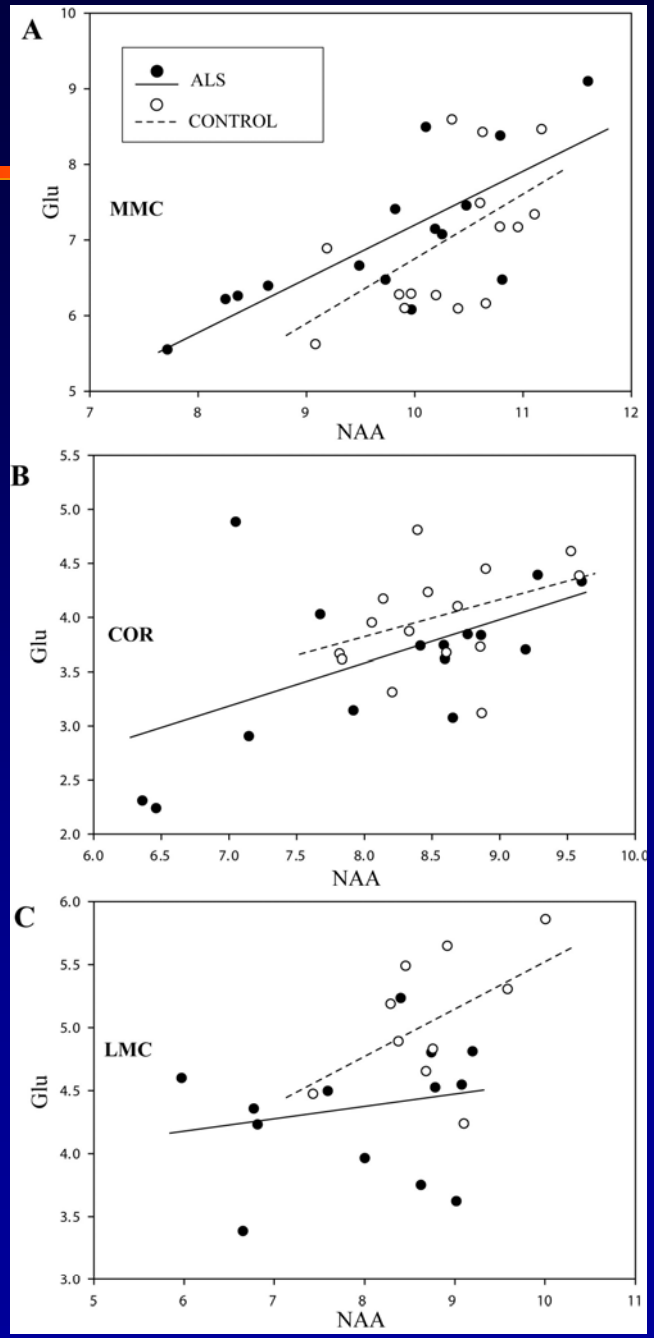

Volumetric ^{1}H *E*cho-*P*lanar-*S*pectroscopic *I*maging (EPSI)

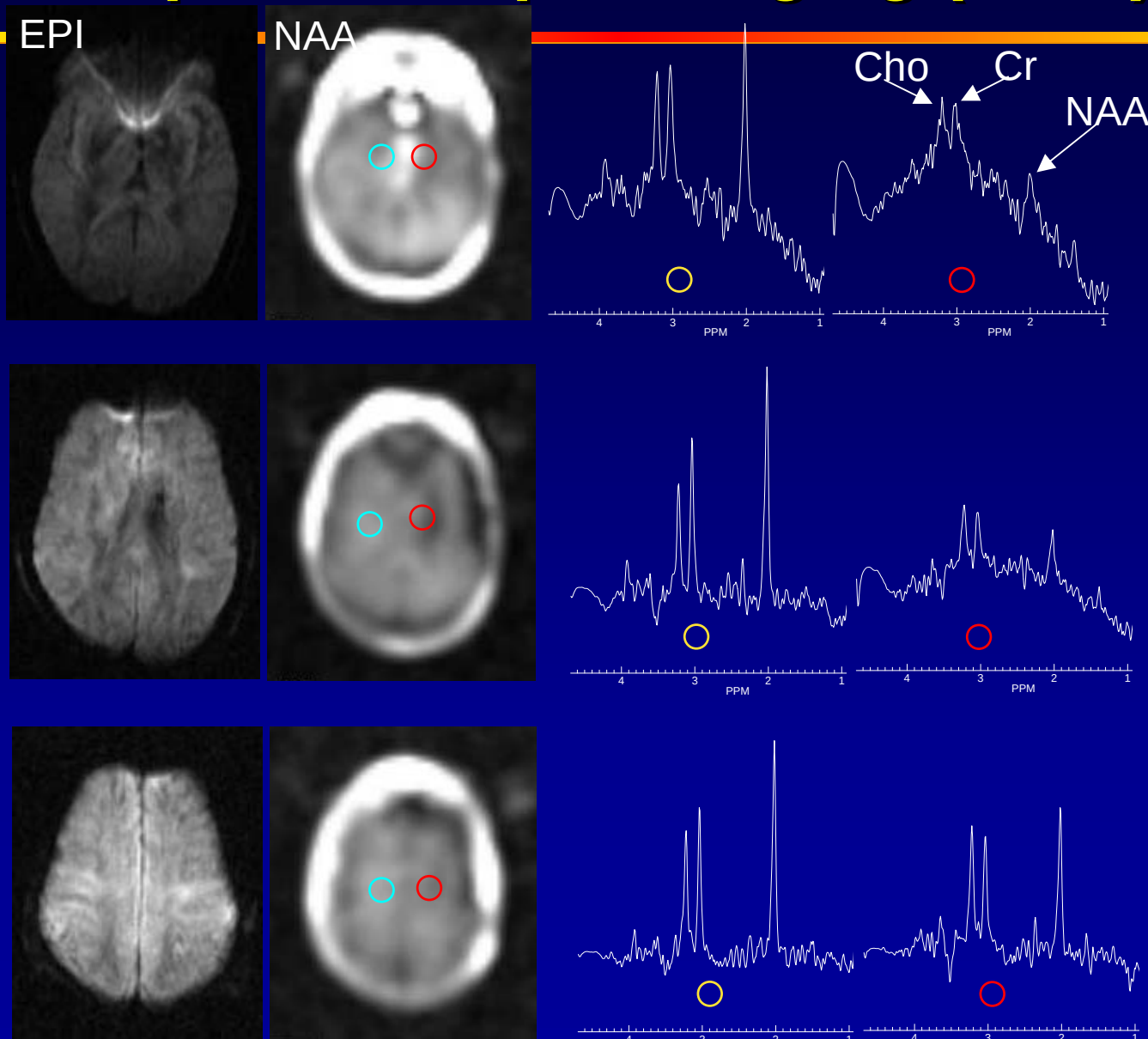

Summary

- Brain atrophy measurements at submillimeter resolution
- Assessment of hippocampal subfields
- Cerebral blood flow measurements at millimeter resolution within minutes
- Reliable detection of glutamate (& glutamine)
- Volumetric metabolite maps