High Field Training Session

Jan 20th to 25th

Thorsten Thiel, Ph.D.

MedSpec® 4T High Field System

4 Tesla Ultra High Field MRI Scanner at
VA Medical Center, San Francisco

Inversion recovery TSE

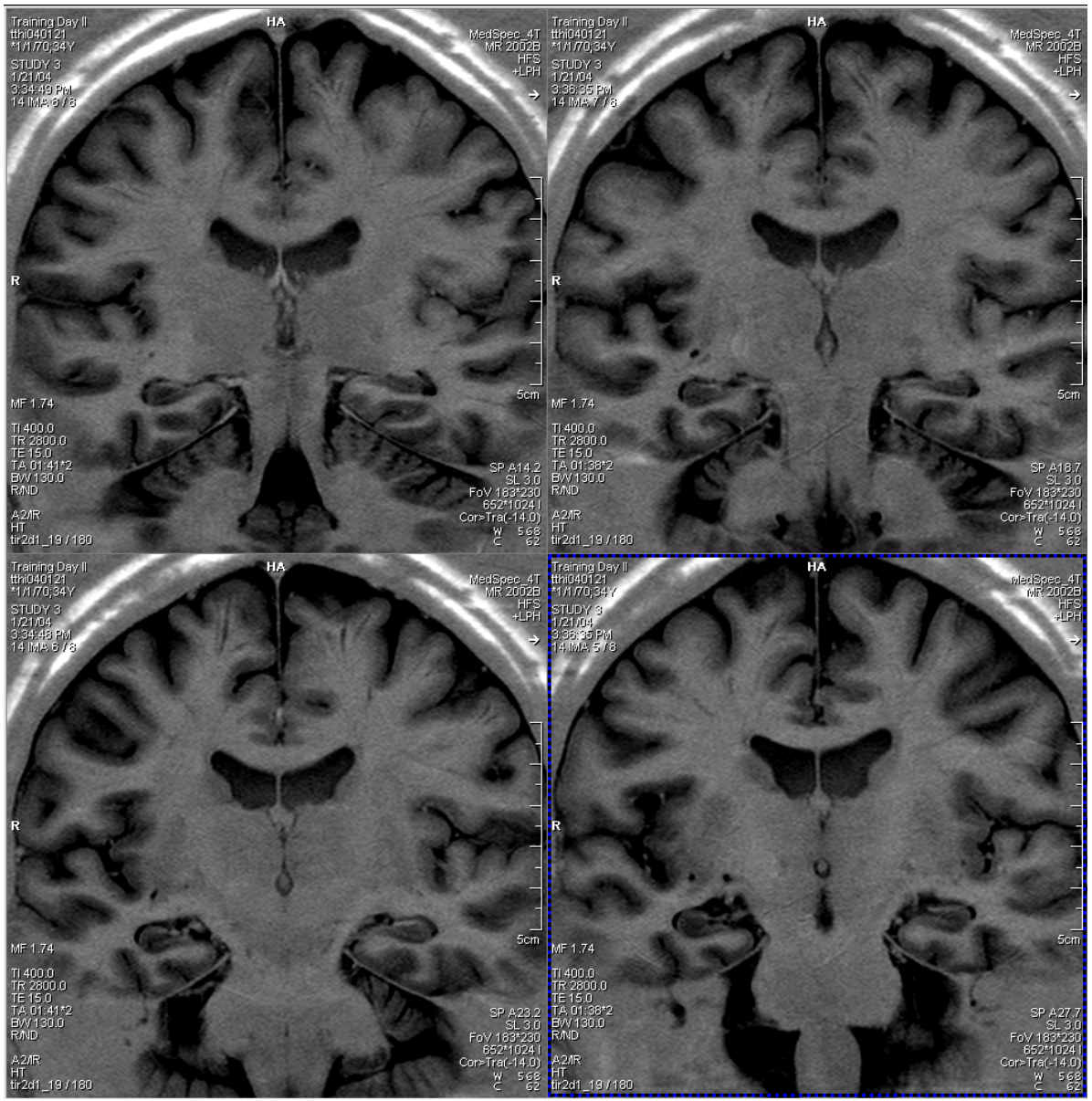

Structural Imaging:

- IR Turbo Spin Echo
- High in plane resolution (400 x 400 µm)
- 3 mm slice thickness
- Scan time: 3:12 min

Courtesy:
VA Medical Center
San Francisco

Inversion recovery Turbo FLASH

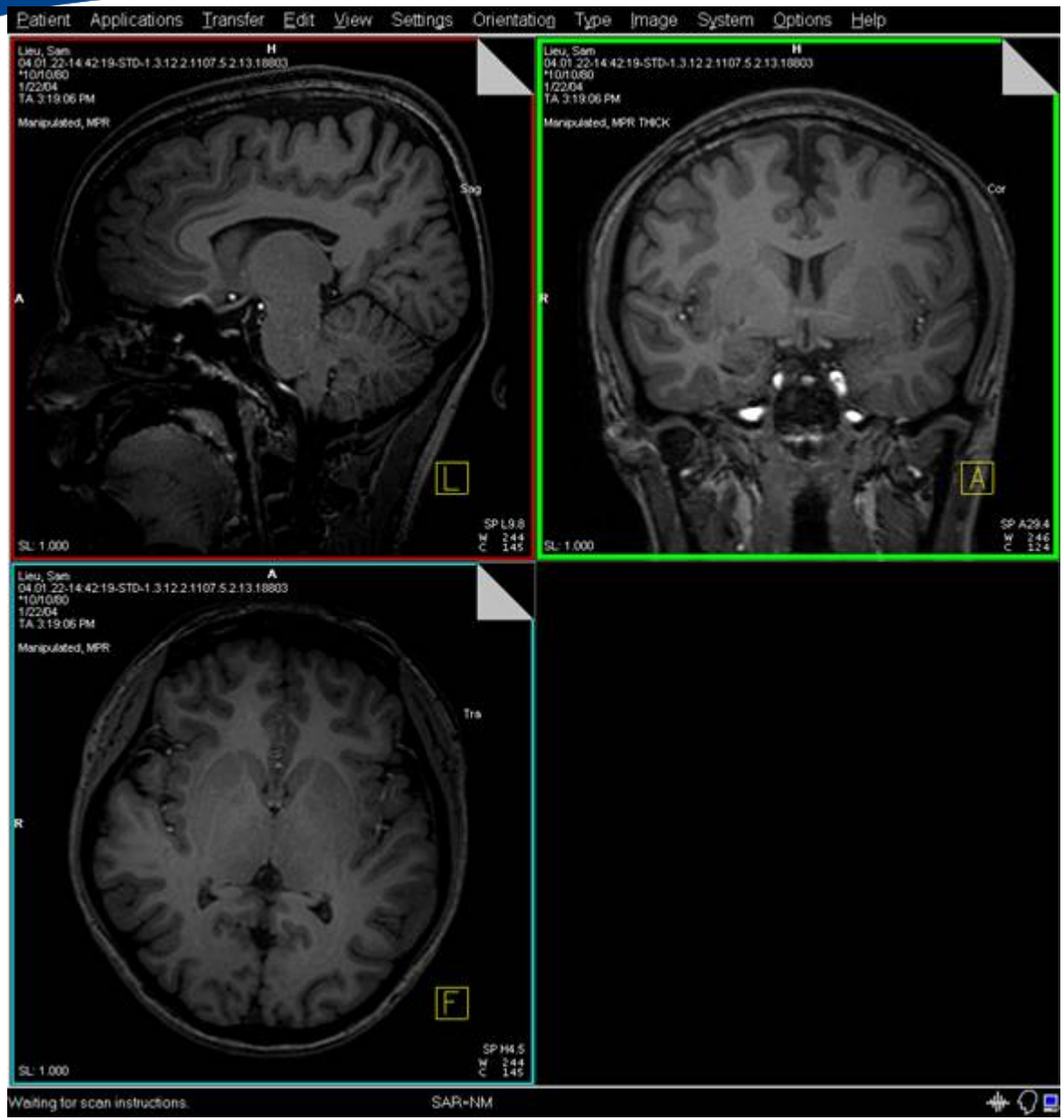

Structural Imaging

MPRAGE:

- IR Turbo FLASH
- High isotropic resolution (1.0 x 1.0 x 1.0 mm)
- Scan time: 7:32 min

Courtesy:
VA Medical Center
San Francisco

Inversion recovery Turbo FLASH

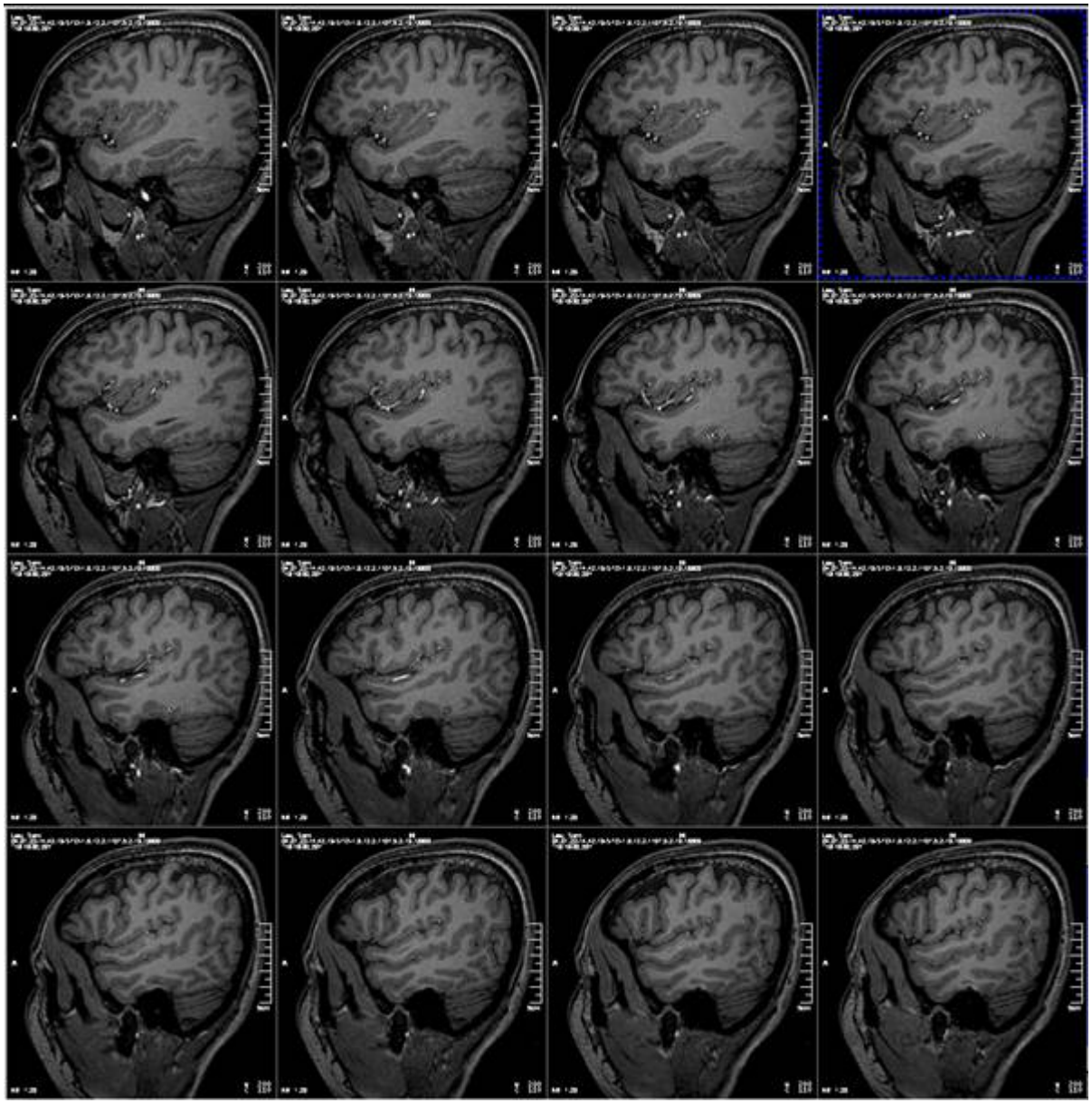

Structural Imaging

MPRAGE:

- IR Turbo FLASH
- High isotropic resolution (1.0 x 1.0 x 1.0 mm)
- Scan time: 7:32 min

Courtesy:
VA Medical Center
San Francisco

Dark Fluid Turbo Spin Echo

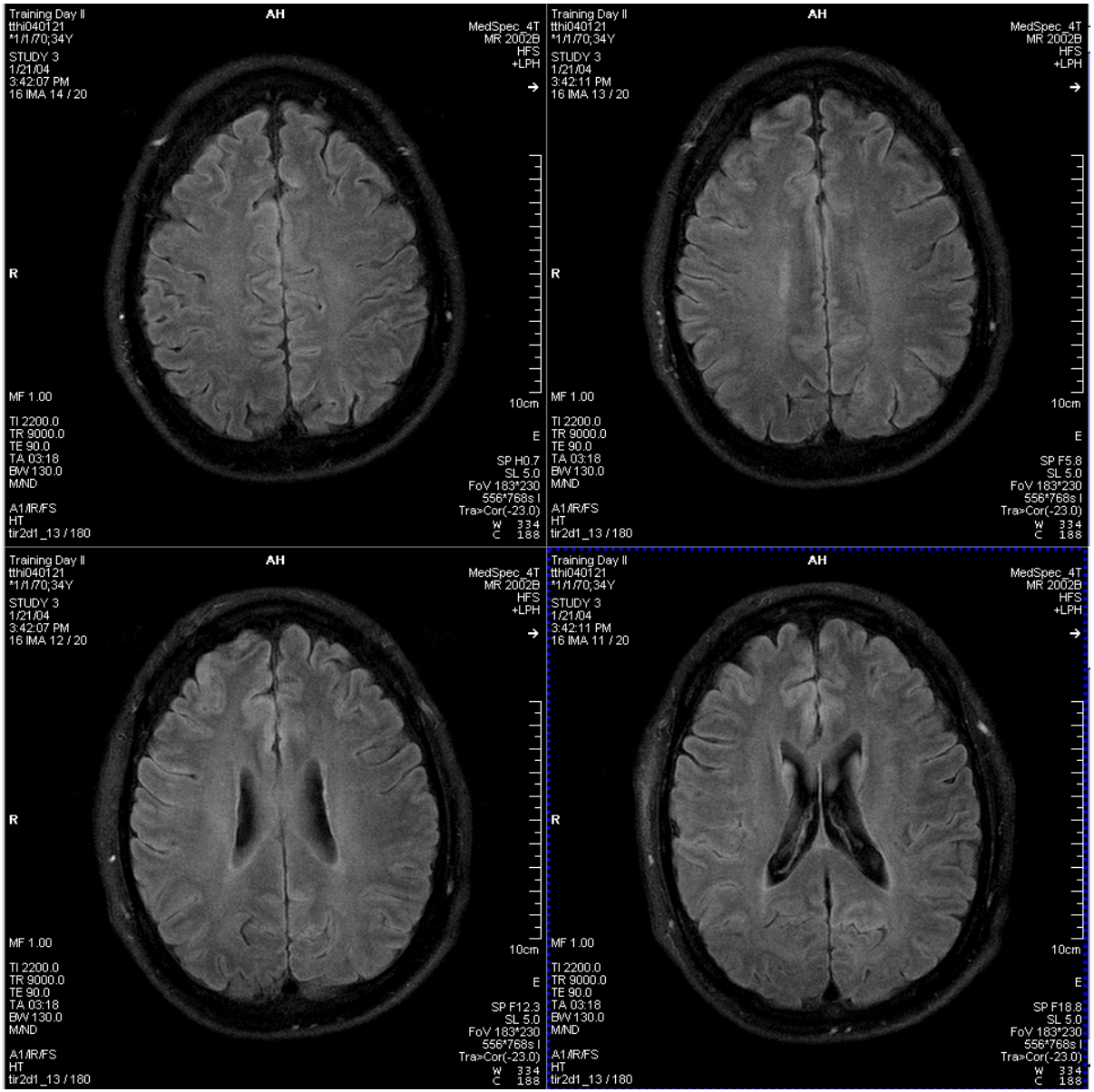

Structural Imaging

FLAIR:

- IR TSE
- in plane resolution (600 x 600 µm)
- Scan time: 3:18 min
- 20 slices
- 5mm slice thickness

Courtesy:
VA Medical Center
San Francisco

Low SAR Hyper Echo Imaging

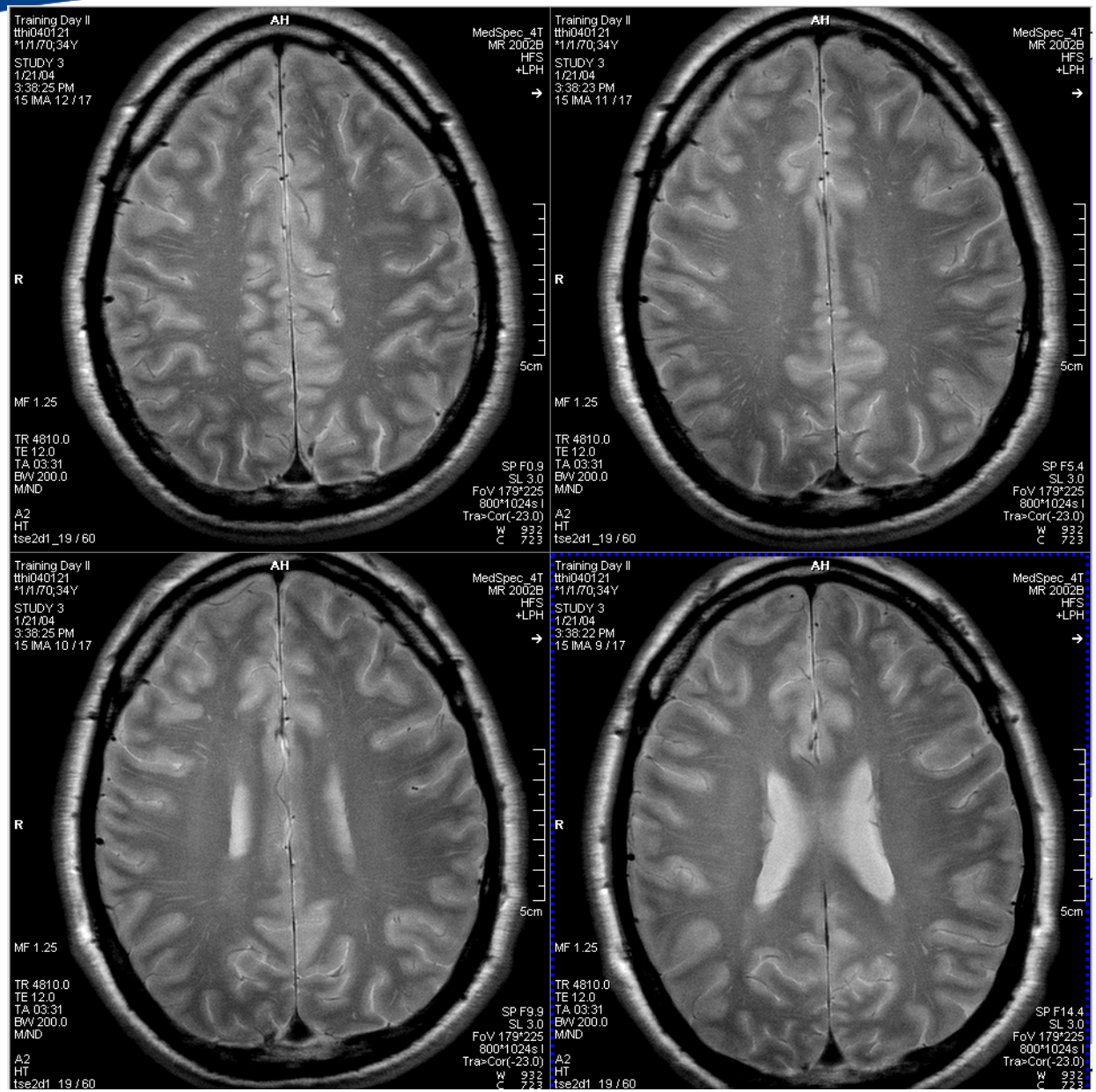

Structural Imaging PD

Proton Density based on low SAR Hyper Turbo Spin Echo Technology:

- Hyper TSE
- in plane resolution (400 x 400 µm)
- Scan time: 3:21 min
- TE 12 ms
- TR 4810 ms
- 17 slices
- 3 mm slice thickness
- Echo train length 19
- SAR 36% !!!

Courtesy:
VA Medical Center
San Francisco

Low SAR 3D T2 Imaging

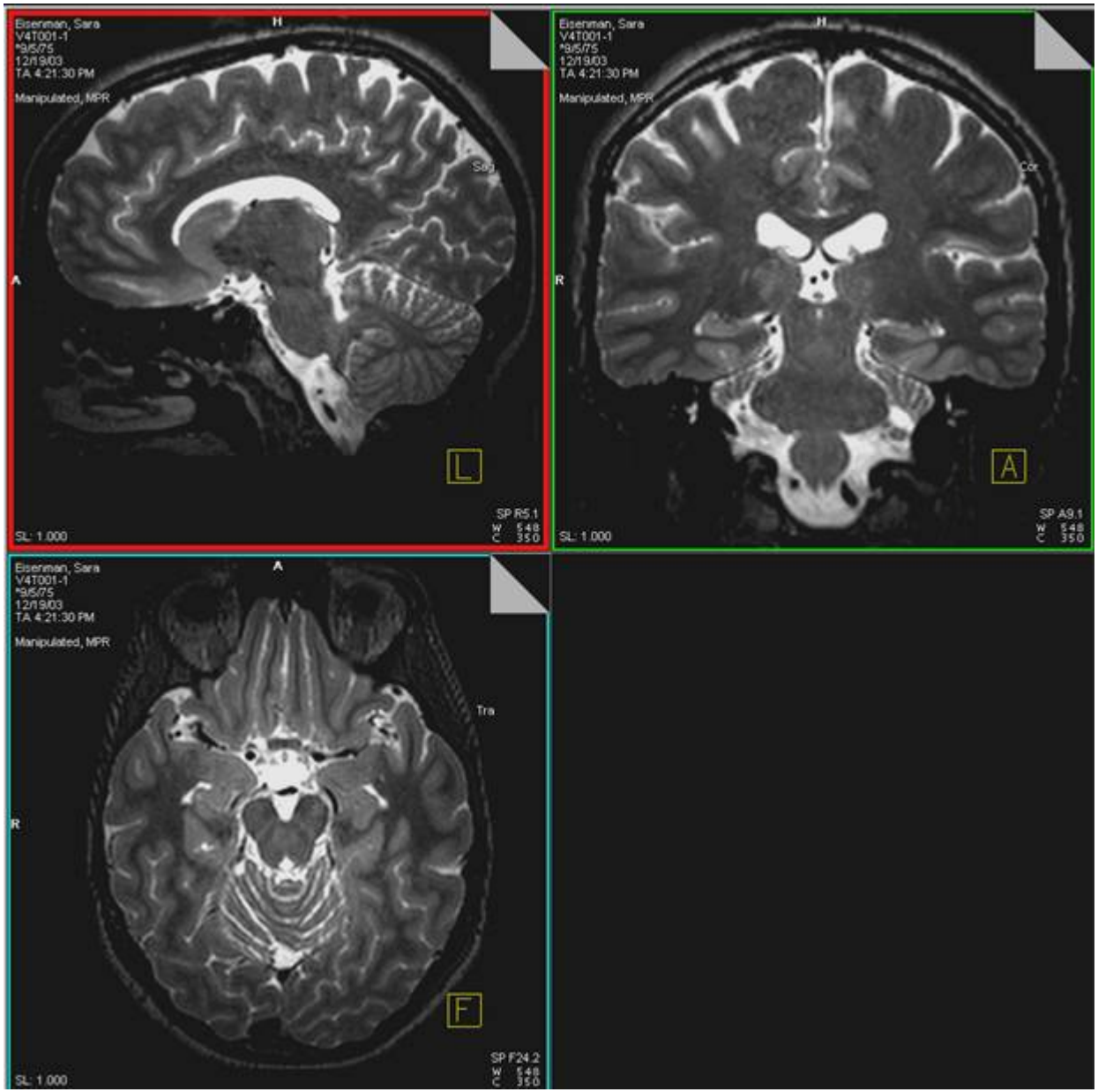

Structural Imaging 3D

High resolution 3D T2 imaging based on low SAR variable flip angle Technology:

- Variable Flip Angle TSE
- Isotropic resolution
  1.0 x 1.0 x 1.0 mm
- Scan time: 9:21 min
- TE 320 ms
- 160 slices
- 1 mm slice thickness
- Echo train length 209
- SAR 59 % !!!

Courtesy:
VA Medical Center
San Francisco

BOLD fMRI

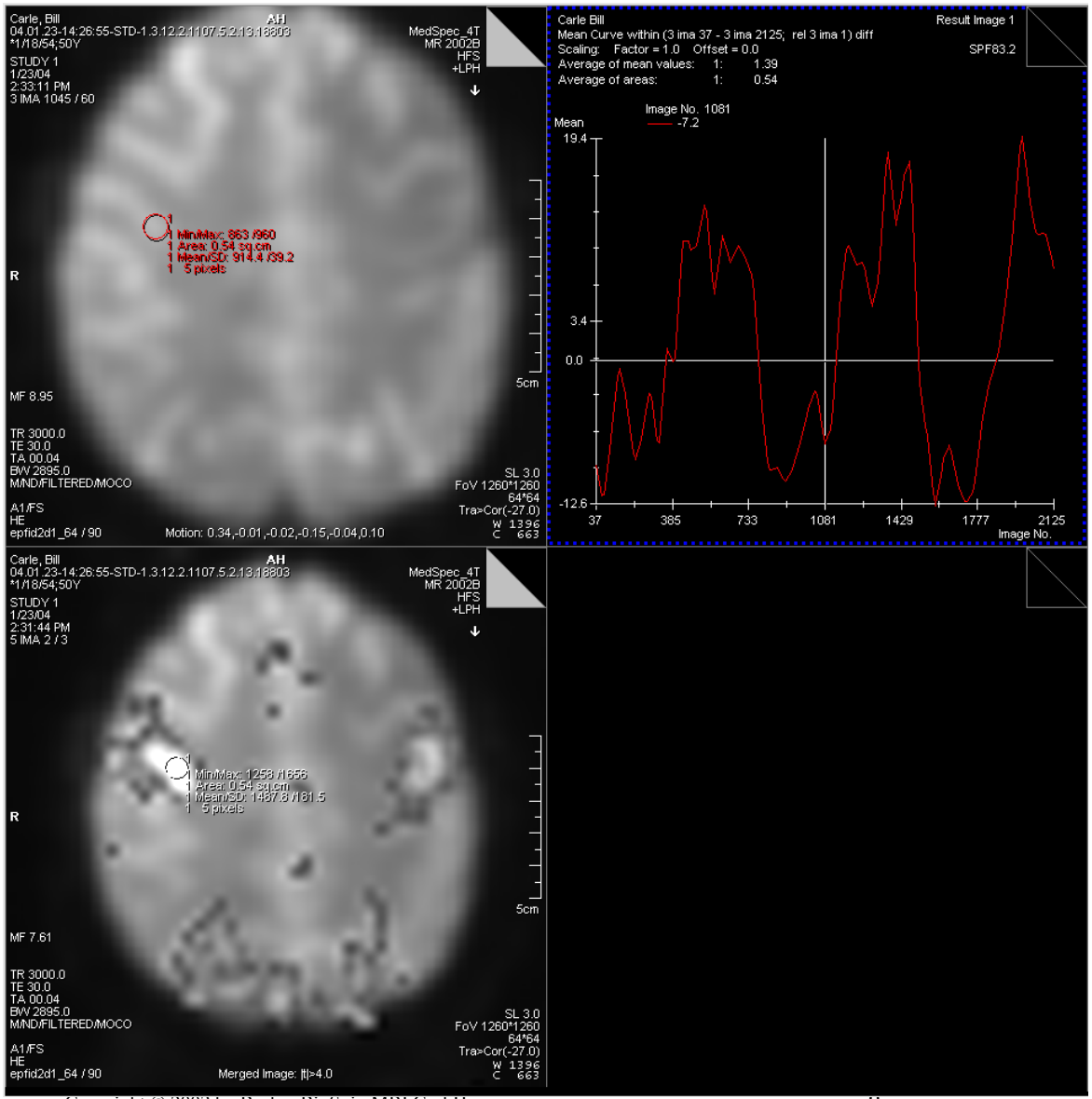

BOLD fMRI experiment using single shot gradient echo EPI

Motor cortex BOLD response during combined visual/motor activation task.
Results from on line t-test.

- Single Shot EPI
- Isotropic resolution
  3.0 x 3.0 x 3.0 mm
- Scan time: 3:00 min
- TE 30 ms
- TR 3000 ms
- 36 slices
- 3 mm slice thickness

Courtesy:
VA Medical Center
San Francisco

Copyright © 2003 by Bruker BioSpin MRI GmbH

BOLD fMRI

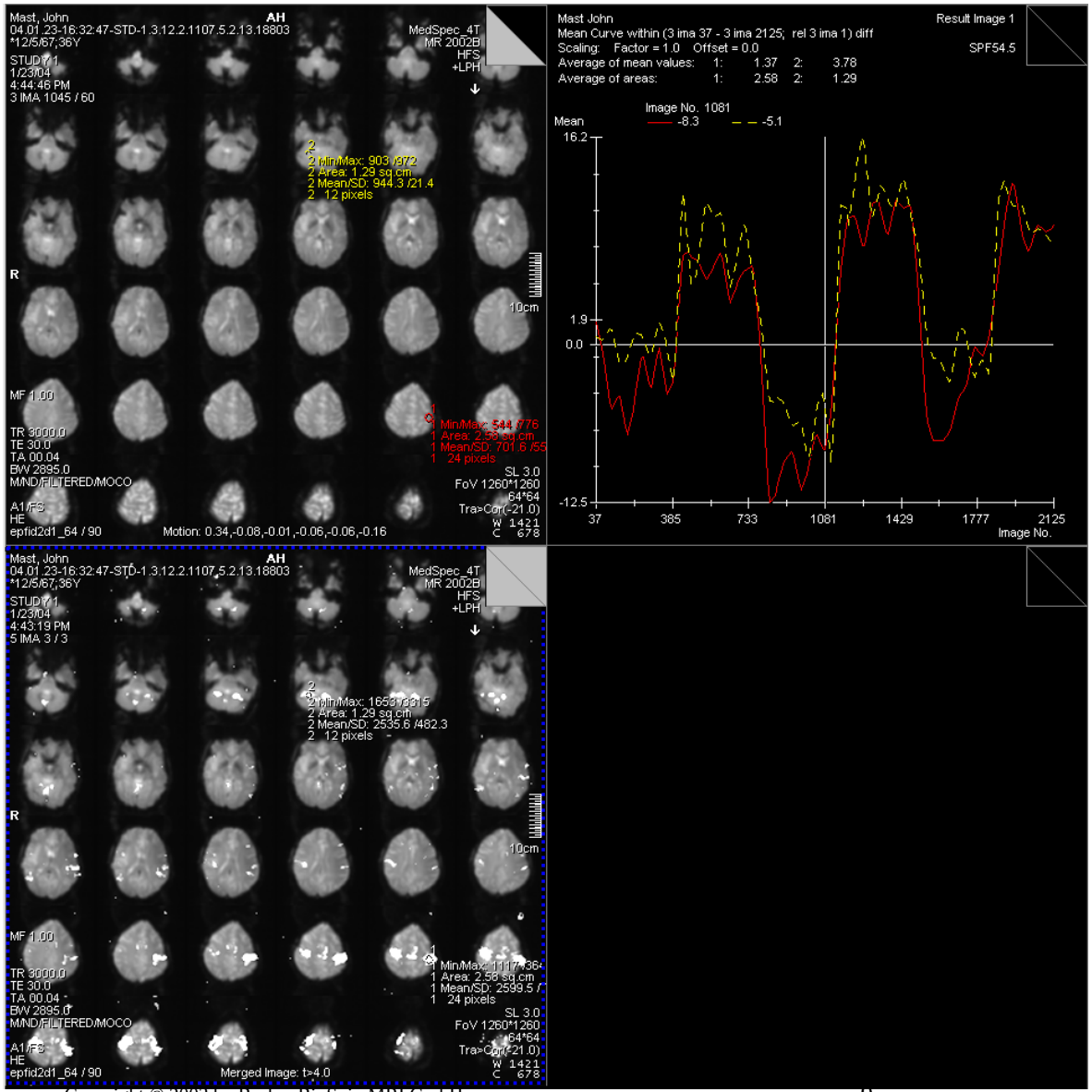

BOLD fMRI experiment using single shot gradient echo EPI

Correlation between activation in cerebellum (yellow) and motor cortex (red) during finger tapping task.
Results from on line t-test.

- Single Shot EPI
- Isotropic resolution
  3.0 x 3.0 x 3.0 mm
- Scan time: 3:00 min
- TE 30 ms
- TR 3000 ms
- 36 slices
- 3 mm slice thickness

Courtesy:
VA Medical Center
San Francisco

Copyright © 2003 by Bruker BioSpin MRI GmbH

Perfusion: Arterial Spin Labeling

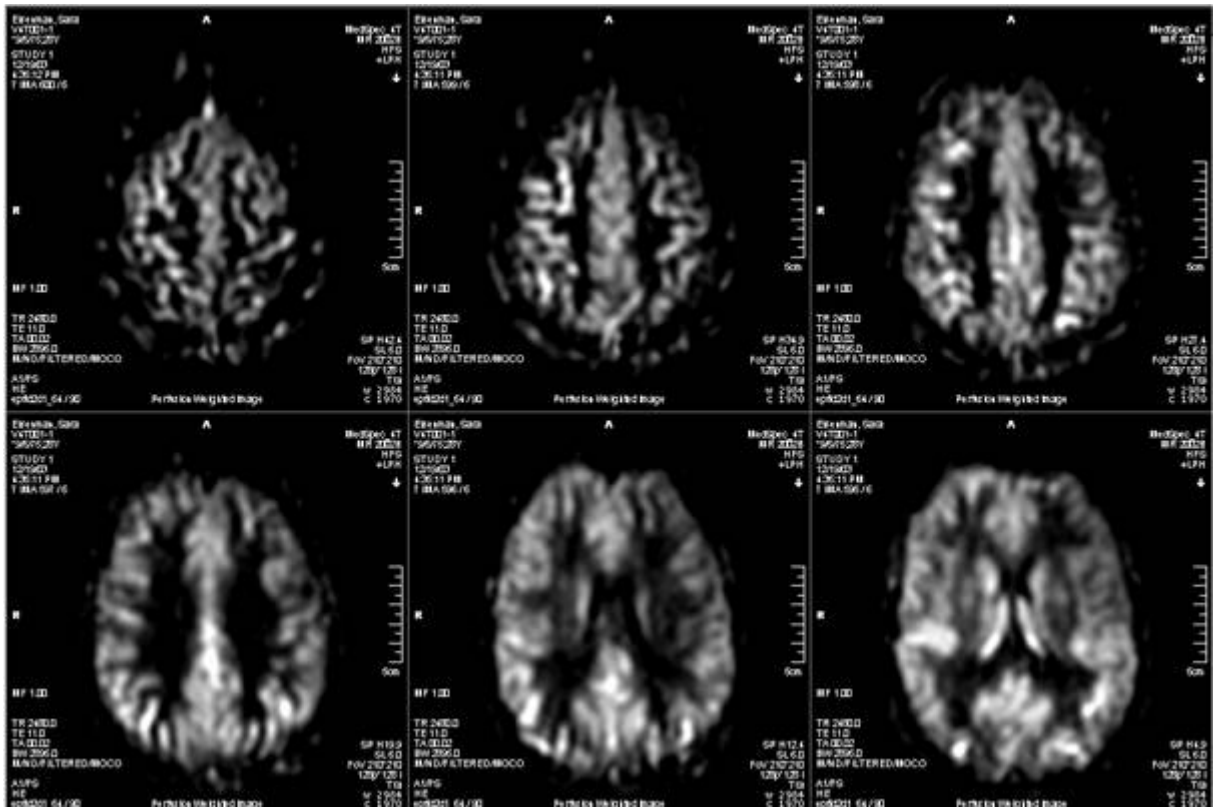

Perfusion experiment based on Arterial Spin Labeling

- Single Shot EPI
- 3.0 x 3.0 mm in plane resolution
- Scan time: 4:12 min
- TE 11 ms
- TR 2500 ms
- 6 slices
- 6 mm slice thickness
- 100 measurements (50 tagged, 50 untagged)
- Real time calculation of perfusion maps

Courtesy:
VA Medical Center
San Francisco

Copyright © 2003 by Bruker BioSpin MRI GmbH

Perfusion: Arterial Spin Labeling

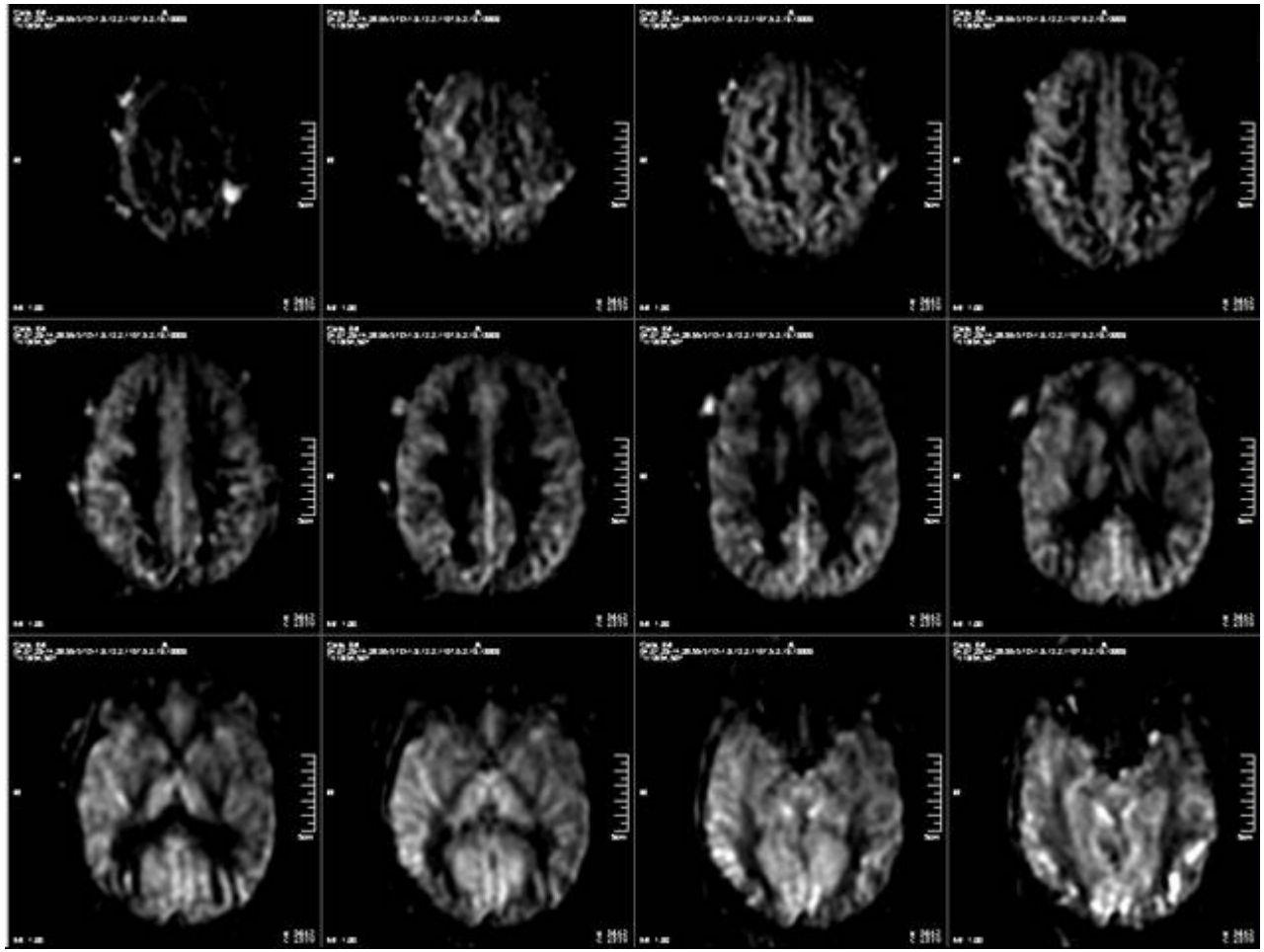

Perfusion experiment based on Arterial Spin Labeling

- Single Shot EPI
- 3.0 x 3.0 mm in plane resolution
- Scan time: 4:52 min
- TE 11 ms
- TR 2700 ms
- 12 slices
- 4 mm slice thickness
- 100 measurements (50 tagged, 50 untagged)
- Real time calculation of perfusion maps

Courtesy:
VA Medical Center
San Francisco

Copyright © 2003 by Bruker BioSpin MRI GmbH

Spiral Imaging

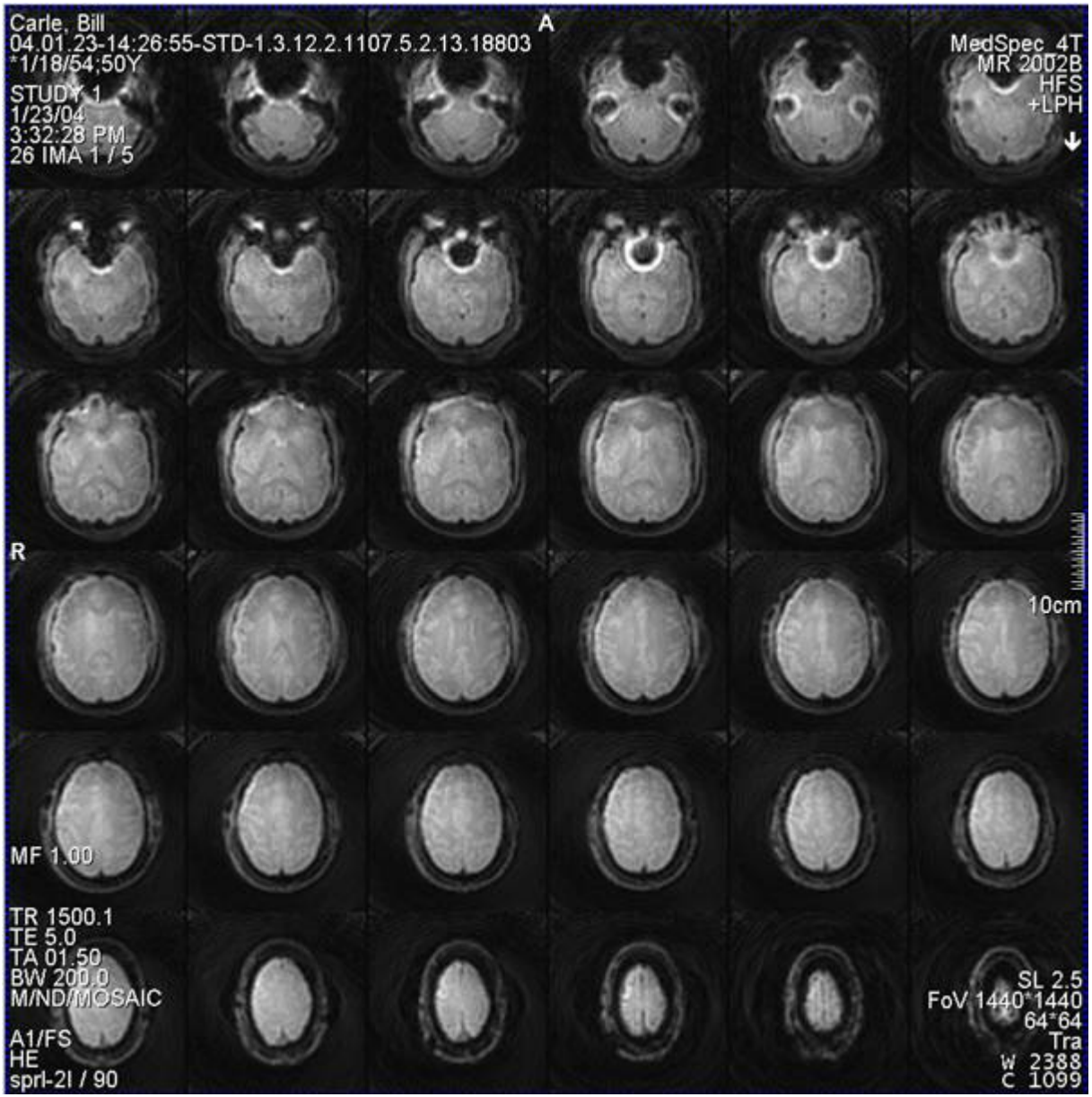

Segmented Spiral Imaging

- 2 segments
- 3.0 x 3.0 mm in plane resolution
- TE 5 ms
- TR 1500 ms
- 36 slices
- 2.5 mm slice thickness

Courtesy:
VA Medical Center
San Francisco

Spiral Imaging

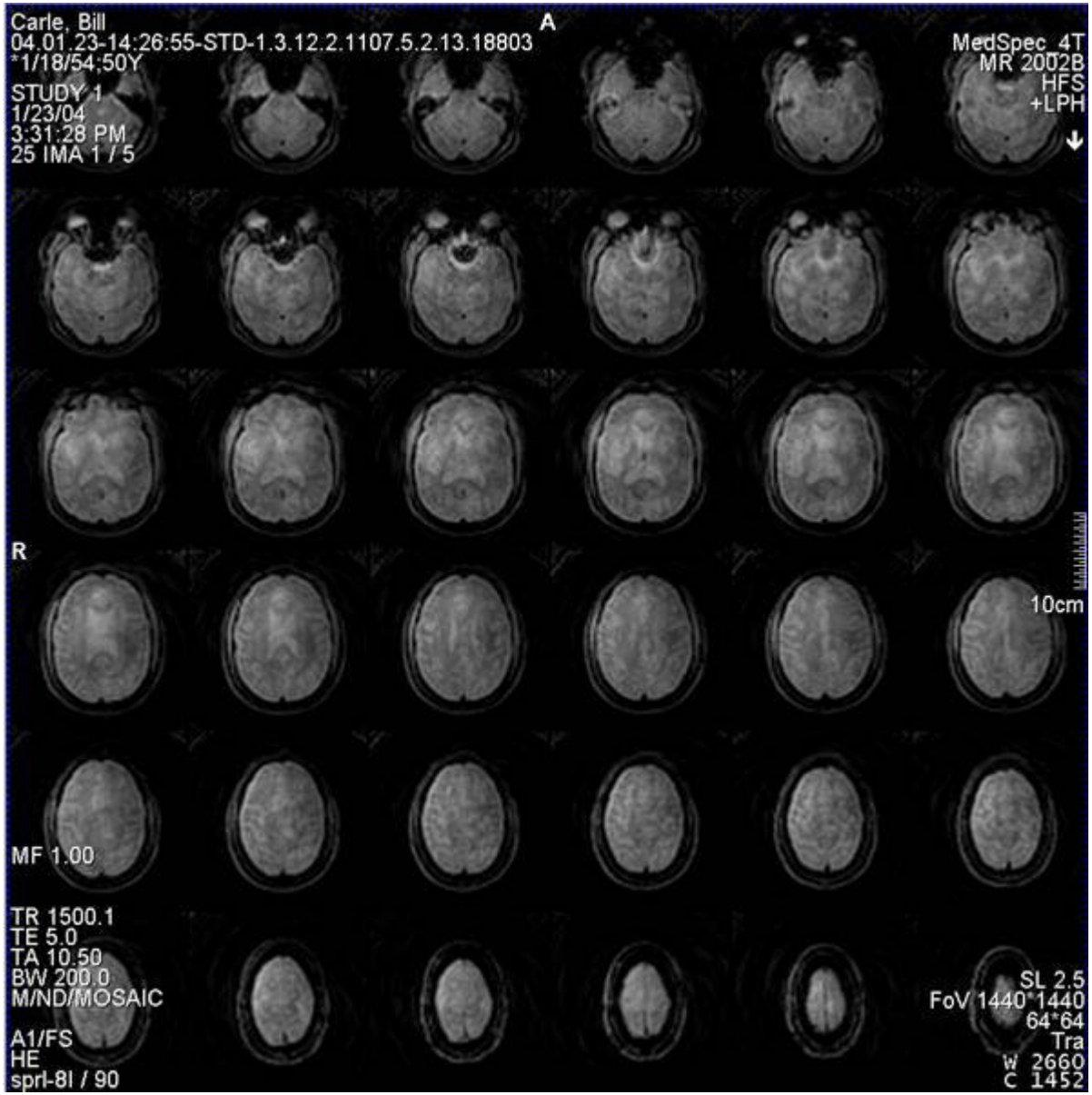

Segmented Spiral Imaging

- 8 segments
- 3.0 x 3.0 mm
  in plane resolution
- TE 5 ms
- 36 slices
- 2.5 mm slice thickness

Courtesy:
VA Medical Center
San Francisco

Single Voxel MRS

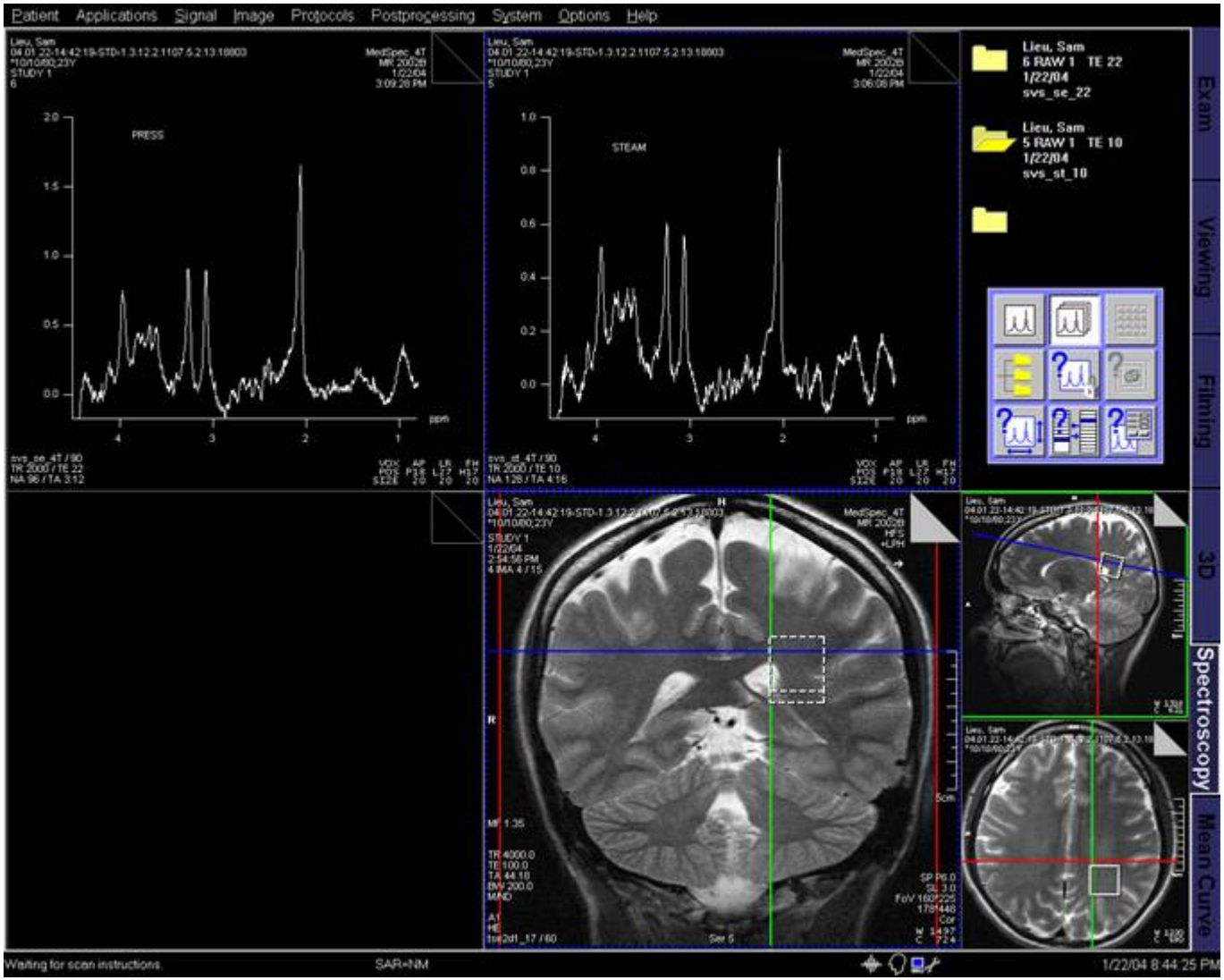

Single Voxel MRS

PRESS (left) vs. STEAM (right)

Occipital Cortex

- 8 segments
- 20 x 20 x 20 mm^3 in plane resolution
- TE 10 ms (STEAM)
- TE 22 ms (PRESS)

Courtesy:
VA Medical Center
San Francisco

Single Voxel MRS

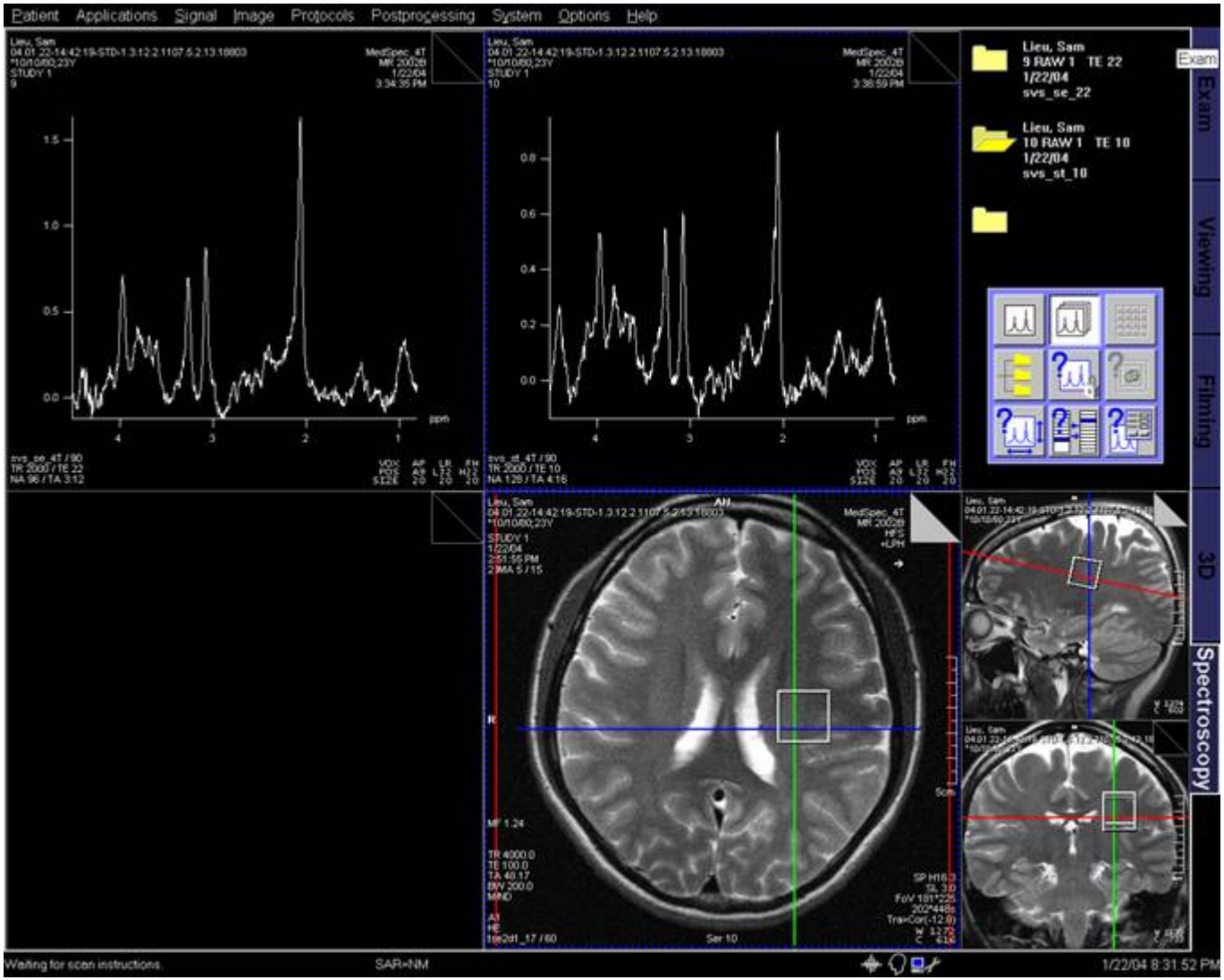

Single Voxel MRS

PRESS (left) vs. STEAM (right)

Motor Cortex

- 20 x 20 x 20 mm^3 in plane resolution
- TE 10 ms (STEAM)
- TE 22 ms (PRESS)

Courtesy:
VA Medical Center
San Francisco

Single Voxel MRS

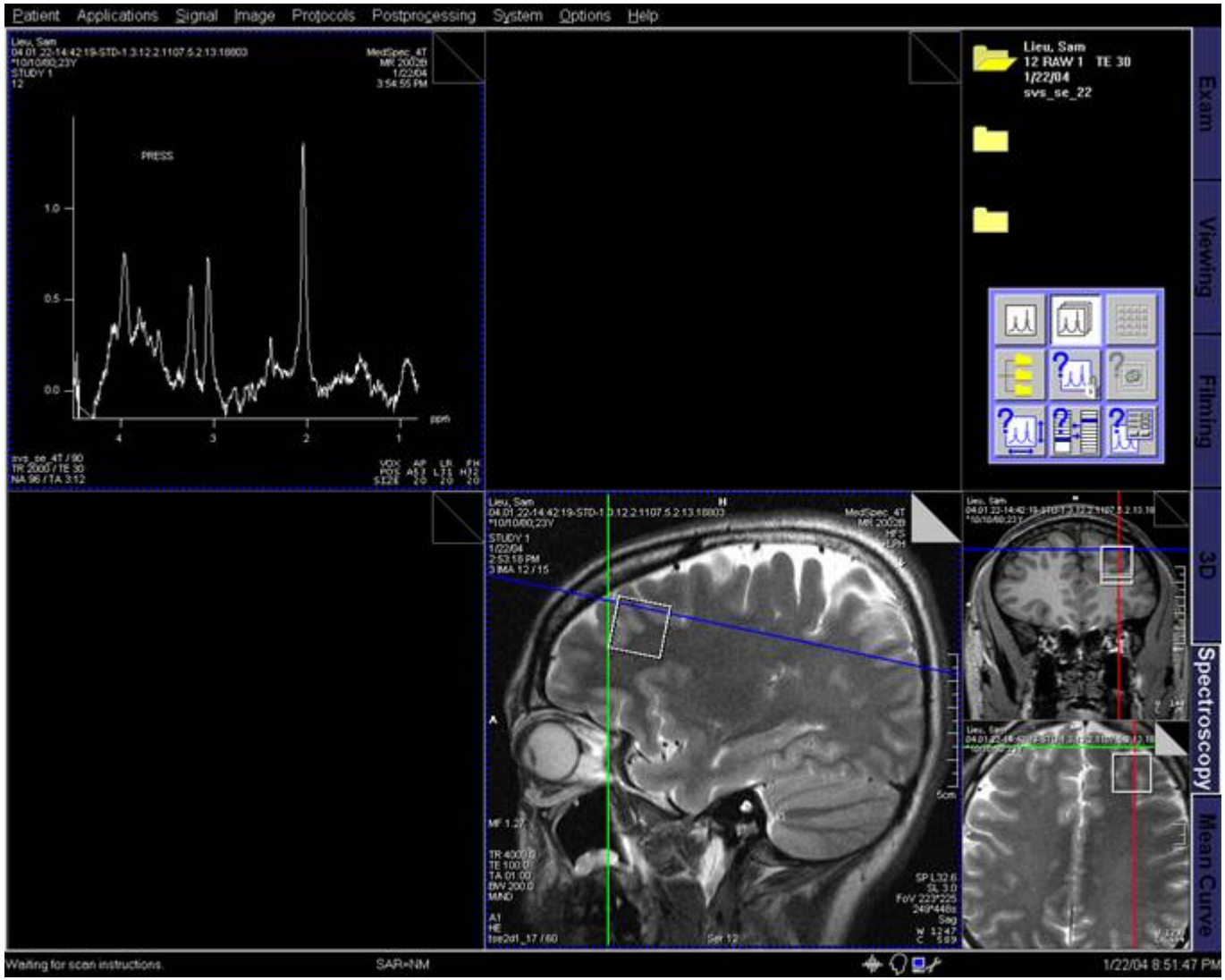

Single Voxel MRS

PRESS

Frontal Cortex

- 20 x 20 x 20 mm^3 in plane resolution
- TE 22 ms

Courtesy:
VA Medical Center
San Francisco

Single Voxel MRS

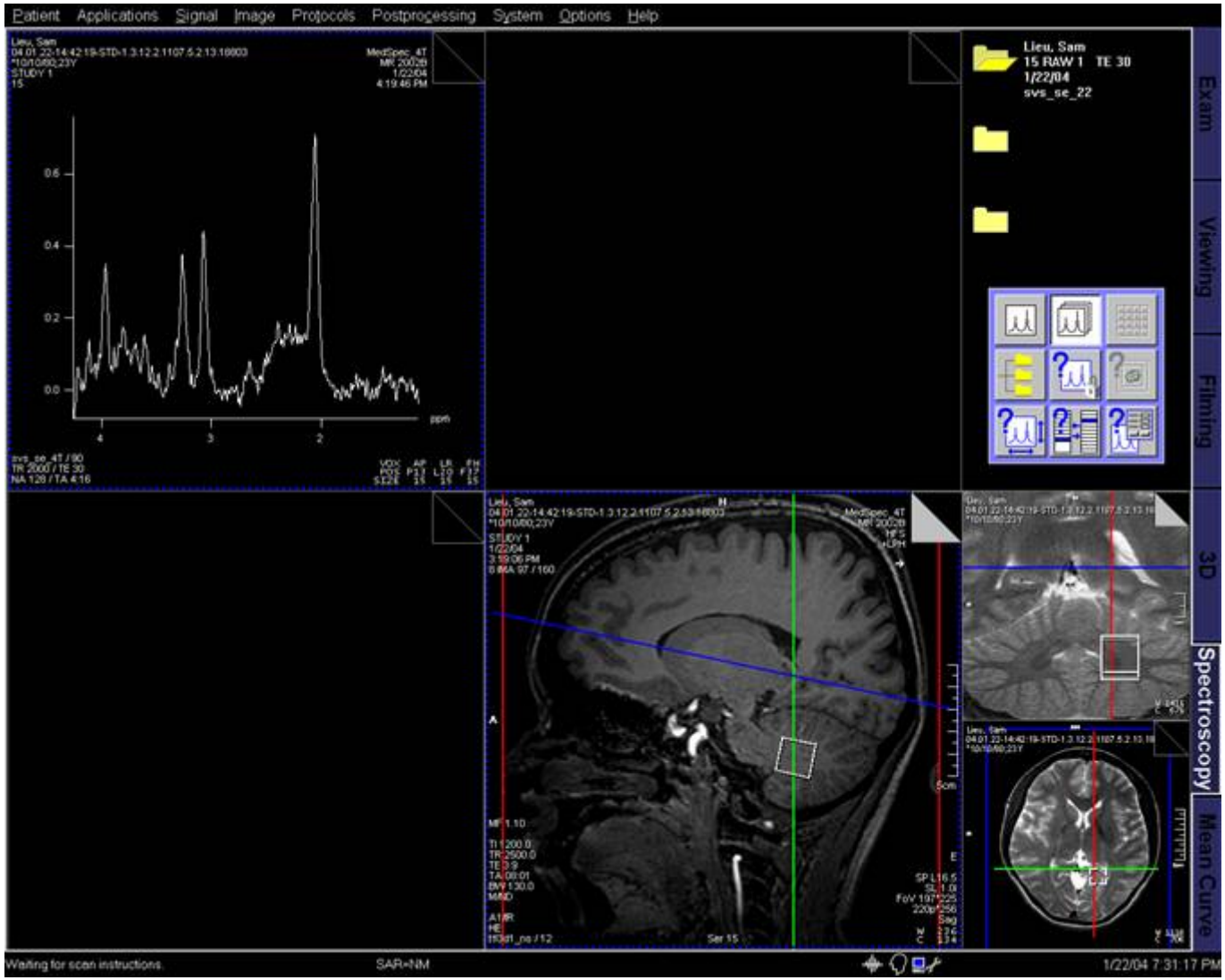

Single Voxel MRS

PRESS

Cerebellum

- 20 x 20 x 20 mm^3 in plane resolution
- TE 22 ms

Courtesy:
VA Medical Center
San Francisco

Copyright © 2003 by Bruker BioSpin MRI GmbH

Chemical Shift Imaging

Chemical Shift Imaging

STEAM volume pre selection

- 10 x 10 x 15 mm³ in plane resolution
- TE 10 ms
- Scan time: 9:21 min

Courtesy:
VA Medical Center
San Francisco

Copyright © 2003 by Bruker BioSpin MRI GmbH

Chemical Shift Imaging

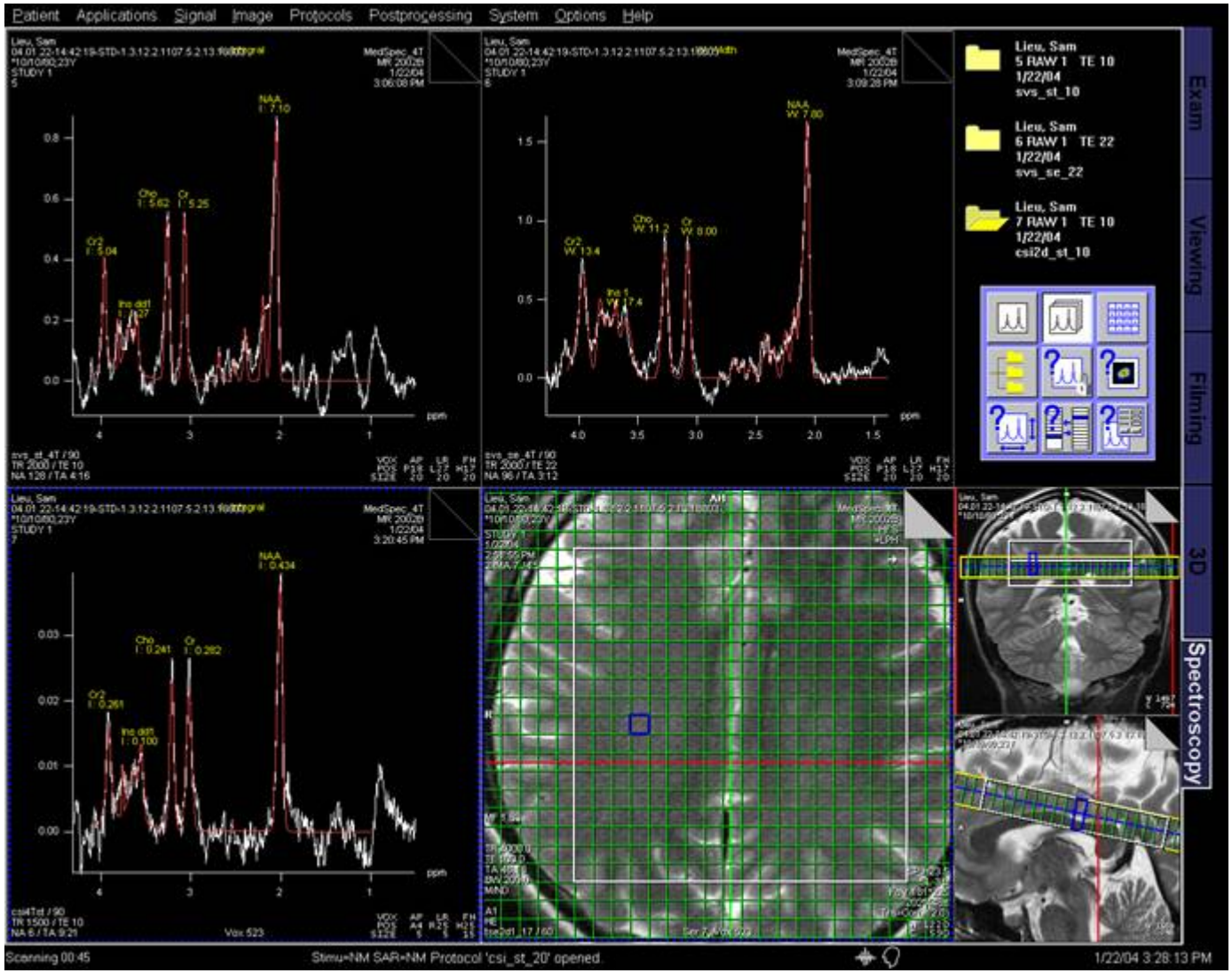

Chemical Shift Imaging

STEAM volume pre selection

- 10 x 10 x 15 mm³ in plane resolution
- TE 10 ms
- Scan time: 9:21 min

Courtesy:
VA Medical Center
San Francisco

Copyright © 2003 by Bruker BioSpin MRI GmbH

Chemical Shift Imaging: Matrix Display

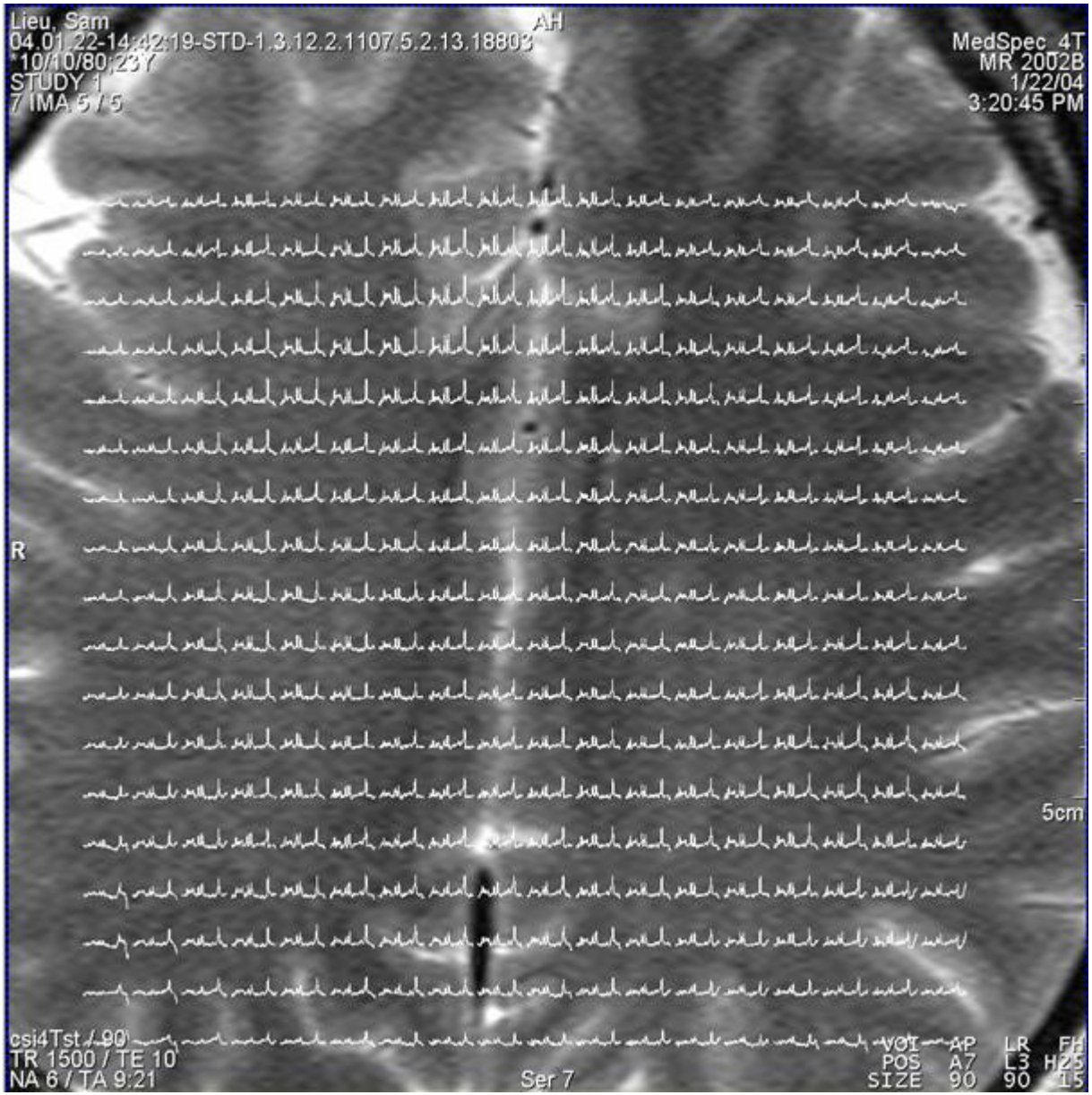

Chemical Shift Imaging

Matrix Display (real spectra)

STEAM volume pre selection

- 10 x 10 x 15 mm^3 in plane resolution
- TE 10 ms
- Scan time: 9:21 min

Courtesy:
VA Medical Center
San Francisco

Chemical Shift Imaging: Matrix Display

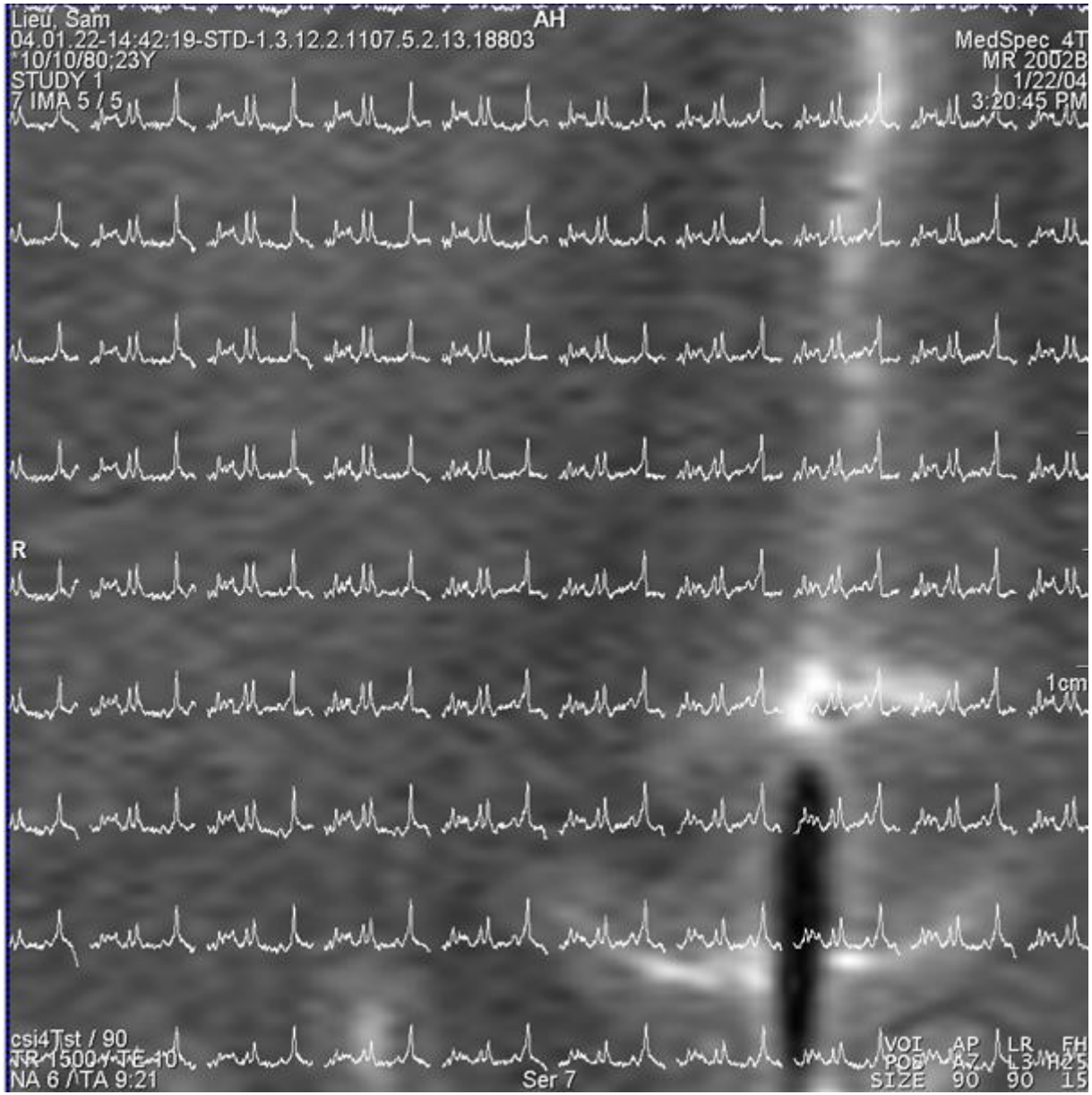

Chemical Shift Imaging

Matrix Display (real spectra)

STEAM volume pre selection

- 10 x 10 x 15 mm^3 in plane resolution
- TE 10 ms
- Scan time: 9:21 min

Courtesy:
VA Medical Center
San Francisco